

THE AAO

FORUM FOR OSTEOPATHIC THOUGHT

JOURNAL



Official Publication of the American Academy of Osteopathy®

TRADITION SHAPES THE FUTURE VOLUME 16 NUMBER 4 DECEMBER 2006

**Pelvic Pain Due to Placement of the
Vaginal Cuff after Hysterectomy**

page 11

Instructions to Authors

The American Academy of Osteopathy® (AAO) Journal is a peer-reviewed publication for disseminating information on the science and art of osteopathic manipulative medicine. It is directed toward osteopathic physicians, students, interns and residents and particularly toward those physicians with a special interest in osteopathic manipulative treatment.

The AAO Journal welcomes contributions in the following categories:

Original Contributions

Clinical or applied research, or basic science research related to clinical practice.

Case Reports

Unusual clinical presentations, newly recognized situations or rarely reported features.

Clinical Practice

Articles about practical applications for general practitioners or specialists.

Special Communications

Items related to the art of practice, such as poems, essays and stories.

Letters to the Editor

Comments on articles published in *The AAO Journal* or new information on clinical topics. Letters must be signed by the author(s). No letters will be published anonymously, or under pseudonyms or pen names.

Book Reviews

Reviews of publications related to osteopathic manipulative medicine and to manipulative medicine in general.

Note

Contributions are accepted from members of the AOA, faculty members in osteopathic medical colleges, osteopathic residents and interns and students of osteopathic colleges. Contributions by others are accepted on an individual basis.

Submission

Submit all papers to Anthony G. Chila, DO, FAAO, Editor-in-Chief, Ohio University, College of Osteopathic Medicine (OUKOM), Grosvenor Hall, Athens, OH 45701.

Editorial Review

Papers submitted to *The AAO Journal* may be submitted for review by the Editorial Board. Notification of acceptance or rejection usually is given within three months after receipt of the paper; publication follows as soon as possible thereafter, depending upon the backlog of papers. Some papers may be rejected because of duplication of subject matter or the need to establish priorities on the use of limited space.

Requirements for manuscript submission:

Manuscript

1. Type all text, references and tabular material using upper and lower case, double-spaced with one-inch margins. Number all pages consecutively.
2. Submit original plus three copies. Retain one copy for your files.
3. Check that all references, tables and figures are cited in the text and in numerical order.
4. Include a cover letter that gives the author's full name and address, telephone number, institution from which work initiated and academic title or position.
5. Manuscripts must be published with the correct name(s) of the author(s). No manuscripts will be published anonymously, or under pseudonyms or pen names.
6. For human or animal experimental investigations, include proof that the project was approved by an appropriate institutional review board, or when no such board is in place, that the manner in which informed consent was obtained from human subjects.
7. Describe the basic study design; define all statistical methods used; list measurement instruments, methods, and tools used for independent and dependent variables.
8. In the "Materials and Methods" section, identify all interventions that are used which do not comply with approved or standard usage.

CD-ROM

We encourage and welcome a CD-ROM containing the material submitted in hard copy form. Though we prefer receiving materials saved in rich text format on a CD-ROM, materials submitted in paper format are acceptable.

Abstract

Provide a 150-word abstract that summarizes the main points of the paper and its conclusions.

Illustrations

1. Be sure that illustrations submitted are clearly labeled.
2. Photos and illustrations should be submitted as a 5" x 7" glossy black and white print with high contrast. On the back of each photo, clearly indicate the top of the photo. If photos or illustrations are electronically scanned, they must be scanned in 300 or higher dpi and saved in .jpg format.

3. Include a caption for each figure.

Permissions

Obtain written permission from the publisher and author to use previously published illustrations and submit these letters with the manuscript. You also must obtain written permission from patients to use their photos if there is a possibility that they might be identified. In the case of children, permission must be obtained from a parent or guardian.

References

1. References are required for all material derived from the work of others. Cite all references in numerical order in the text. If there are references used as general source material, but from which no specific information was taken, list them in alphabetical order following the numbered journals.
2. For journals, include the names of all authors, complete title of the article, name of the journal, volume number, date and inclusive page numbers. For books, include the name(s) of the editor(s), name and location of publisher and year of publication. Give page numbers for exact quotations.

Editorial Processing

All accepted articles are subject to copy editing. Authors are responsible for all statements, including changes made by the manuscript editor. No material may be reprinted from *The AAO Journal* without the written permission of the editor and the author(s).



3500 DePauw Boulevard
Suite 1080
Indianapolis, IN 46268
(317) 879-1881
FAX (317) 879-0563

AMERICAN ACADEMY OF OSTEOPATHY®

Kenneth H. Johnson, DO, FAAO..... President
Claudia L. McCarty, DO, FAAO ..President-Elect
Stephen J. Noone, CAEExecutive Director

EDITORIAL ADVISORY BOARD

Raymond J. Hruby, DO, FAAO
Denise K. Burns, DO
Stephen M. Davidson, DO
Eileen L. DiGiovanna, DO, FAAO
Eric J. Dolgin, DO
William J. Garrity, DO
Stefan L.J. Hagopian, DO
Hollis H. King, DO, PhD, FAAO
John McPartland, DO
Steve Paulus, DO, MS
Paul R. Rennie, DO, FAAO
Mark E. Rosen, DO

THE AAO JOURNAL

Anthony G. Chila, DO, FAAO..... Editor-in-Chief
Stephen J. Noone, CAE Supervising Editor
Diana L. Finley, CMPManaging Editor

The AAO Journal is the official publication of the American Academy of Osteopathy®. Issues are published in March, June, September, and December each year.

Third-class postage paid at Carmel, IN. Postmaster: Send address changes to: American Academy of Osteopathy®, 3500 DePauw Blvd., Suite 1080, Indianapolis, IN., 46268. Phone: 317-879-1881; FAX: (317) 879-0563; e-mail snoone@academyofosteopathy.org; AAO Website: http://www.academyofosteopathy.org

The AAO Journal is not itself responsible for statements made by any contributor. Although all advertising is expected to conform to ethical medical standards, acceptance does not imply endorsement by this journal.

Opinions expressed in *The AAO Journal* are those of authors or speakers and do not necessarily reflect viewpoints of the editors or official policy of the American Academy of Osteopathy® or the institutions with which the authors are affiliated, unless specified.

THE AAO FORUM FOR OSTEOPATHIC THOUGHT
JOURNAL
Official Publication of the American Academy of Osteopathy®

TRADITION SHAPES THE FUTURE • VOLUME 16 NUMBER 4 DECEMBER 2006

A PEER-REVIEWED JOURNAL

The Mission of the American Academy of Osteopathy® is to teach, advocate, and research the science, art and philosophy of osteopathic medicine, emphasizing the integration of osteopathic principles, practices and manipulative treatment in patient care.

IN THIS ISSUE:

AAO Calendar of Courses4
Contributors6
Component Societies' CME Calendar24

EDITORIAL

View from the Pyramids: *Anthony G. Chila, DO, FAAO*5

REGULAR FEATURES

Dig On7
Letter to the Editor8
From the Archives10
Book Review30
Elsewhere in Print31
2006 Journal Index32

SCIENTIFIC PAPER/THESIS (FAAO)

Pelvic Pain Due to Placement of the Vaginal Cuff after Hysterectomy:
Case Report and Osteopathic Manipulative Approach to Treatment.....11
George J. Pasquarello, DO, FAAO

CLINICAL PRACTICE

Non-Operative Management of Spinal Stenosis18
Philip E. Greenman, DO, FAAO

THE STUDENT PHYSICIAN

OMT for Post-mastectomy Lymphedema and Rib Pain21
Danielle Bradshaw, OMS-IV and Karen Snider, DO

The Use of OMT in Patients with Osteoarthritis25
Tahira Zaidi, OMS-IV and Stuart F. Williams, DO

Advertising Rates for The AAO Journal
Official Publication

of The American Academy of Osteopathy®
The AOA and AOA affiliate organizations and members of the Academy are entitled to a 20% discount on advertising in this Journal.

Call: The American Academy of Osteopathy®
(317) 879-1881 for more information.

Subscriptions: \$60.00 per year (USA)
\$78.00 per year (foreign)

Advertising Rates:	Size of AD:
Full page \$600 placed (1) time	7 1/2 x 9 1/2
\$575 placed (2) times	
\$550 placed (4) times	
1/2 page \$400 placed (1) time	7 1/2 x 4 3/4
\$375 placed (2) times	
\$350 placed (4) times	
1/3 page \$300 placed (1) time	2 1/4 x 4 3/4
\$275 placed (1) times	
\$250 placed (4) times	
1/4 page \$200 placed (1) time	3 1/3 x 4 3/4
\$180 placed (2) times	
\$150 placed (4) times	
Professional Card: \$60	3 1/2 x 2
Classified: \$1.00 per word	

American Academy of Osteopathy® Calendar of Events

- Jan 11-14 - *Contemporary OMT at the Contemporary*, Ann L. Habenicht, DO, FAAO, Program Chair
- Feb 16-18 - *Diagnosis of Muscle Imbalance and Exercise Prescription The Greenman Protocol* at AZCOM, Brad Sandler, DO
- Mar 19-21 - *Visceral/Manual-Thermal* in Colorado Springs – Kenneth E. Lossing, DO, Program Chair
- Mar 21 – *Facilitated Positional Release* in Colorado Springs – Stanley Schiowitz, DO, FAAO, Program Chair **NEW 6-Hour Course**
- Mar 21-25 – *AAO Convocation* in Colorado Springs – George Pasquarello, DO, FAAO, Program Chair
- Apr 27-29 – *Osteopathic Treatment of Headache* at PCOM – Dennis J. Dowling, DO, FAAO
- Jun 8-10– *Muscle Energy-Counterstrain* at PCOM/ Georgia Campus - Walter C. Ehrenfeuchter, DO, FAAO and Edward K. Goering, DO
- Jul 13-15– *Masters in Pediatric Osteopathic Practices* at CCOM – Stephanie Waecker, DO
- Sep 29 – One-day course – *OMT without an OMT Table* in San Diego – Ann L. Habenicht, DO, FAAO
- Sep 30 – Oct 4 – *AOA Convention* in San Diego – John E. Balmer, DO, Program Chair
- Dec 1-3 – *Visceral Manipulation: Colon* in San Francisco - Kenneth Lossing, DO

***AAO Editorial Advisory Board and
the AAO Staff wish
you and your family the
Best of the Holiday Season***

THE COLLECTED WRITINGS OF ROBERT G. THORPE, DO, FAAO

Edited by:
John D. Capobianco, DO, FAAO and
Sonia Rivera-Martinez, DO

From the Preface: Whether you realize it or not, by picking up this book you have entered into the world of Dr. Thorpe's musculoskeletal organ. In his world, the musculoskeletal system holds a central position that defines man. He refers to this system as the organ of behavior and action, for with it, our brain and mind become a person. In this capacity, the musculoskeletal organ is central to conceptual thought between our very being and our internal and external environments. It also becomes the protector in fight or flight. Further, he expands on the role of the musculoskeletal organ in relation to endocrine disease, stress, autonomic nervous system, infection and chronic disease. He fittingly describes the significance of the musculoskeletal organ, as without it, all other organ systems "could do nothing but lie in a gelatinous heap and pulsate and quiver."

Sonia Rivera-Martinez, DO
Mineola, NY

Order Form

Collected Writings of Robert G. Thorpe, DO, FAAO @ \$30.00 + \$7 S/H in U.S. Please add \$1.00 for each additional book ordered.

Write or call for foreign shipping rates.

Total \$ amount of order: _____

Shipping Information:

Name _____

Street Address _____

(NO P.O. Box #s)

City _____ State _____ Zip _____

Daytime Phone _____

Payment Information:

VISA MC CHECK

Card No. _____

Expiration Date _____

For your copies, contact:
American Academy of Osteopathy®
3500 DePauw Blvd., Suite 1080
Indianapolis, IN 46268
phone: (317) 879-1881; FAX: (317) 879-0563
order online: www.academyofosteopathy.org



View from the Pyramids

Anthony G. Chila

Learning

In contemporary teaching, much use is made of visual presentation. In recent years, this has led to a greatly increased and sophisticated use of *PowerPoint* formats. The prevalence of this format is such that many audiences seem to feel that “all I need to know” is contained in the various images and texts utilized in the given presentation.

In a recent article from *infoComm International AV WEEK*: October 22-28, 2006 (<http://www.infocomm.org>), Dave Paradi discussed concerns about the use of this method (How to avoid *Death by PowerPoint*). Paradi listed five common problems associated with PowerPoint Presentations:

- Problem #1: The presenter focused more on the visuals than the content.
- Problem #2: The audience can't clearly see the slides.
- Problem #3: The audience is distracted by the visuals.
- Problem #4: Pointer movement on the screen.
- Problem #5: Dropping into the program.

With respect to Problem #1, Paradi urged that speakers prepare using a proper approach to the presentation. Analysis of the background and composition of the audience is critical in order to determine points that will move the audience from where they are to the presenter's desired end point. Next, appropriate research should be done to provide backup for each of the key points of the presentation. The remainder of Paradi's observations offered suggestions for improvement in using PowerPoint Presentations for Problems 2-5.

A century ago, sophisticated audiovisual support and the computer did not exist. It might be safely said that the most important piece of equipment available was the brain of the speaker. The following remarks are cited:

“It must be understood at the outset that the work is designed primarily for the student who is but beginning to be interested in the new method of healing. Hence to those who are already practitioners of that method the matter contained in the following pages may not seem particularly new nor satisfying in the way of suggesting ideas of an immediately practical nature. Yet we are not without hope that even to the latter class there are many points of interest which will help to throw light upon some of the many vexing problems that

continually arise in the experience of the busy practitioner.

Neither should it be assumed that the work is intended to treat exhaustively of the numerous questions of theory that are associated with the science. That is entirely beyond the scope of a work that is prepared especially for him who, under the circumstances of a comprehensive curriculum of study, crowded into a period of time all too short, must of necessity limit his reading in all subjects to those texts which give but a comparatively brief treatment. This work, therefore, is rather but an outline of the various subjects that are most closely related to the fundamentals of the science, with suggestions as to the direction further investigation should take.

Experience has justified the author's method in using the narrative style, while subserving the convenience of the student by putting the keywords and phrases in different type.”¹

Many years have now passed since the osteopathic profession began to work toward the production of a text that would reflect the thought of the profession, support for its premises, and acceptability to its students and practitioners. *Foundations for Osteopathic Medicine* was the outcome. Preparation is underway for publication of a Third Edition (October 2009). A change in editorship has been announced. Initial consultation with the publisher, Lippincott Williams Wilkins, encourages critical review and appropriate revision in order to meet expectations of the profession's audience. It is hoped that the effort of past contributors will find satisfaction in the work accomplished in the first two editions, renewal of effort by those who would like to continue, and new contributors who will accept the ongoing challenge.

1. G.D. Hulett: *Principles of Osteopathy*, 4th Edition. Preface to Fourth Edition. Copyright 1906 by C.M. Turner Hulett.

Contributors

George J. Pasquarello. Pelvic Pain Due To Placement Of The Vaginal Cuff After Hysterectomy: Case Report And Osteopathic Manipulative Approach To Treatment. This Scientific Paper/Thesis was submitted in partial fulfillment of requirements for Fellowship in the American Academy of Osteopathy. The author received status as Fellow in 2002. The author discusses the potential injury of the levator ani and obturator internus muscles in pelvic pain following attachment of the vaginal cuff after hysterectomy. Reviews of pelvic anatomy, hysterectomy procedure and vaginal cuff attachment are provided. A case history illustrates the beneficial outcome for the patient resulting from interdisciplinary cooperation in diagnosis and treatment. (p. 11).

Philip E. Greenman. Non-Operative Management Of Spinal Stenosis. An aging population is presenting the community of physicians with chronic problems, the management of which can be addressed conservatively or by intervention. In the case of spinal stenosis, the author notes that spinal stenosis surgery is the most rapidly increasing surgical procedure performed by spinal surgeons. Report is provided on a series of 15 consecutive patients presenting with disabling back and leg pain, and significant reduction in activities of daily living. In following a conservative management program, each received specific osteopathic manipulative treatment and a structured exercise program. All were spared surgical intervention, and all noted pain reduction and increased walking tolerance. (p. 18).

Danielle Bradshaw and Karen Snider. Osteopathic Manipulative Treatment (OMT) For Post-Mastectomy Lymphedema And Rib Pain: Case Report. The authors note that lymphedema is a chronic condition which cannot be cured. The presentation of this report on management of a female patient, status post-mastectomy, utilizing OMT indicates the achievement of increased comfort and function. Anatomical review is provided. Mechanisms of lymphedema, manual lymphatic drainage and OMT are discussed. (p. 21).

Tahira Zidi and Stuart Williams. The Use Of Osteopathic Manipulative Treatment (OMT) In Patients With Osteoarthritis: Case Report. The authors note that Osteoarthritis (OA) is one of the most common joint disorders. Recognized as a common chronic disease in an elderly population, there is no cure, and the tendency is worsening with aging. Thus, OA is a major cause of disability. The presentation of this report on management of a young female patient applies principles of OMT to address pain thought to be contributing to restricted joint motion through increased muscle tension and shortening, resulting in increased inflammation and edema. (p. 25).

Regular Features

DIG ON. Theodore Jordan, DO offers readers a look at the inventor side of Andrew Taylor Still. "The Old Doctor" offered various devices for the advancement of the practice of osteopathic medicine. In such effort, safety and comfort for the patient and the practitioner were of prime consideration. "Dr. A.T. Still's Treating Chair" was one such contribution. This presentation offers a view of treatment considerably different from approaches in use today. (p. 7)

FROM THE ARCHIVES. *The Practice of Osteopathy* (Carl Philip McConnell and Charles Clayton Teall, 1906) addresses *Lumbo-abdominal neuralgia* in a manner quite consistent with the approach offered by George J. Pasquarello (p. 11). Absent the use of sophisticated contemporary imaging procedures, McConnell and Teall reaffirm for today's students and practitioners the necessity to appreciate and understand the anatomical implications of clinical presentations. (p. 10).

BOOK REVIEW. International considerations prevail in the reviews of two publications. Each publication spans at least one decade of intensified professional activity. From Russia, the focus is on theory and method associated with *Osteopathy in the Cranial Field (OCF)*. From England, the focus is on *Low Back Pain: some real answers*. (p. 30).

ELSEWHERE IN PRINT. In this survey, readers can: Speculate on the future of human evolution; Explore the link between nasal allergy and sinus infection; Consider recent developments and therapeutic implications in chronic musculoskeletal pain in chronic fatigue syndrome. (p. 31).

CME CREDIT. In response to reader requests, AAOJ will offer CME Credit to readers completing the enclosed quiz. At this time, 1 Hour II-B Credit will be offered, with request for upgrade as AAOJ qualifications are reviewed by the *American Osteopathic Association*. (p. 17).

Dig On



Dr. A. T. Still's Treating Chair

Theodore Jordan

Dr. A. T. Still was a thinker and an inventor. He designed several devices to advance the practice of osteopathic medicine to make various manipulations and treatments easier. These include the osteopathic swing, the uterine spoon, and one invention coined "Dr. Still's Treating Chair," which facilitated manipulation of the spine. This chair was used extensively in Kirksville during the first decade of the 20th century and a description of its use gives us interesting clues as to how patients were treated by A. T. Still and his students at that time.

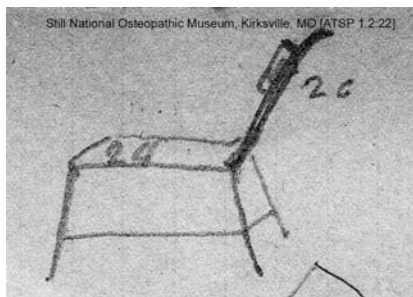


Figure 1: A sketch from A. T. Still's notebooks (no date). Assumed to be an early representation of the treatment chair [ATSP 1.2.22 pg4]. Reproduced with permission of the Still National Osteopathic Museum.

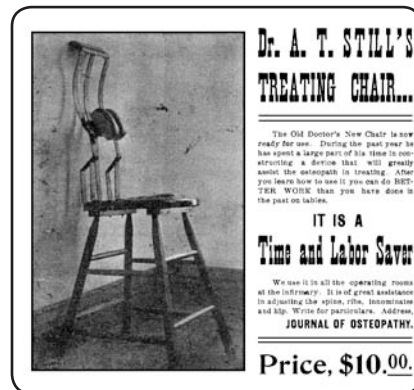A sketch of this chair is found in Dr. Still's notebooks that are preserved at the Still National Osteopathic Museum in Kirksville (Figure 1). Although these notebooks have no date, they are probably Dr. Still's first rough designs. The chair was later produced for sale and pictures of the chair can be seen in advertisements published in the "Journal of Osteopathy" (figure 2). In addition to the pictures, a description of the chair's use was published in Dr. G. D. Hulett's textbook of the period:

"A method of special value requiring special apparatus has come into use within recent years. A stool with a back provided with a sliding part arranged to

fit closely on either side of the row of spinous processes and a seat bottom unyielding in nature and with a wedge shaped piece to prevent the ischia from lateral sliding, constitutes the apparatus. These are provided for in Dr. Still's chair. With the adjustable piece at the point of lesion and the physician in front or behind, the shoulders are grasped and by a figure-of-eight movement the body is rotated, the only movable part of the body being that above the fulcrum, the remainder being held up by the pressure against the latter and downward upon the stool. In this treatment the spine the fulcrum represents the lever arm, the "breaking" occurring more or less entirely at the fulcrum. By sliding the movable part up or down each of the involved vertebrae may be acted upon. Owing to the interference presented by the arms of the standard supporting the movable fulcrum, there is little possibility of drawing the patient too far posteriorly and hence doing harm."¹

Several things should be noted from this description. First, the technique described would best be classified today as a high-amplitude, low-velocity technique for the spine. No thrusting is mentioned, but rather a large "figure-of-eight" motion is engaged around a solidly established fulcrum. Elsewhere in Dr. Hulett's textbook, he admonishes against rapid manipulative movements as "not advantageous", except for a few possible exceptions.² Dr. Still referred to the "pop" heard with some manipulation as "breaking the current".³ Dr. Hulett's description implies that such a "pop", or "break" may have been achieved when manipulating a patient's spine on this chair. It is surprising that no mention is made of palpation near the fulcrum, because other authors of the time specifically instruct osteopathic practitioners to let the palpating hand guide the forces used during manipulations, and not to lose the feel of the tissues at any point during manipulation.⁴

Figure 2: Dr. Still's Chair. From an advertisement in *The Journal Of Osteopathy*, 1902 [July;9(7): 12]. Reproduced with permission of the Still National



Osteopathic Museum.

Dr. Hulett also describes how A.T. Still used this chair to treat pelvic dysfunctions. "The operator held one of the patient's ischia firmly on the seat of the chair, while the operator's other arm lifted up on the patient's trunk to pull the wedged sacrum upward, therefore freeing the sacrum from between the two ischia. With the upward traction, a lateral motion was employed with a little rotation. The wedge on the seat was designed to prevent lateral sliding of the pelvis during this treatment."⁵

As mentioned in the advertisement (Figure 2), this chair was reportedly once used in all of the treatment rooms of the American School of Osteopathy's infirmary. Despite their apparent popularity a century ago, none of these treatment chairs are held in the Still National Osteopathic Museum's collection, nor known to exist today.

References

1. Hulett GD. *A Textbook of the Principles of Osteopathy*, 4th ed. Journal Printing Company. Kirksville, MO. 1906. p 281.
2. Hulett GD. *A Textbook of the Principles of Osteopathy*, 4th ed. Journal Printing

- Company. Kirksville, MO. 1906. pp 145-6.
3. Hulett GD. *A Textbook of the Principles of Osteopathy*, 4th ed. Journal Printing Company. Kirksville, MO. 1906. p 207.
 4. McConnell CP. Significance of principles. *JAOA*. 1917. 16:1:933.
 5. Hulett GD. *A Textbook of the Principles of Osteopathy*, 4th ed. Journal Printing Company. Kirksville, MO. 1906. pp 351-2. □

Letter to the Editor

Dear Editor,

It is always a pleasure to read Theodore R. Jordan's latest thoughts. In *Sacroiliac Mechanics Revisited*, *AAOJ* June 2006 p 11-17, Dr. Jordan proposes that that the conceptual model of sacral subluxation is invalid except in (presumably rare) cases of gross sacral instability.

In December 2004 *JAOA*, I presented data on prevalence of pelvic asymmetries and the 80-year history of research from three disciplines that supports it.¹ A subluxed or sacral shear would most closely fit Lloyd and Eimerbrink's Type III and TB patterns, where the sacral base is more unlevel than any femoral head unleveling. Amongst a low back pain population, the combined frequency of those two groups varied from 34% to 12% depending on what degree of sacral base unleveling one considers significant. I would not describe this occurrence as "rare". Whether the SI joint can be "mobilized" remains an open question for me, as does the place of prolotherapy in SI joint stabilization.

While the osteopathic framework in which I live still has "holes" in it, I have the slowly growing and evolving sense that the "patches", as they emerge, are all continuous in the mathematical sense with the broader fabric of osteopathic thought. For this reason I trust the scientific evidentiary process, though it can be maddeningly slow. This letter reflects my impatience at not being yet able to fully merge a treatment and conceptual model.

John H. Juhl, DO
625 Madison Avenue, Ste 10A
New York, NY 10022

Reference

1. Juhl JH, Cremin TI, Gamber, R. Prevalence of frontal plane pelvic postural asymmetry—Pt. 1, *JAOA*. 2004. 194:10:411-421. □

Contemporary OMT January 11-14, 2007

The Contemporary Hotel at
Walt Disney World®
Lake Buena Vista, FL

NEW Course *Bring your MOST difficult Case!*

Course Description: Level II

This innovative new Academy course will have you addressing your patient's needs by looking at the tissue type of dysfunction and using techniques to address those dysfunctions. New techniques will be presented along with a review of pertinent anatomy/physiology (why it works). Diagnosis of joint, "muscle" and fascial dysfunctions will be addressed. HVLA, ME, CS, FPR, Still, MFR, Cranial and energy/fluid techniques will be presented. There will be an opportunity for the participants to "bring your most difficult case" to the faculty for troubleshooting. This program merges parts of the popular OMT Update with new treatment ideas. This is a course for those physicians looking for something new, those wishing to "tune up their fingers" and those planning to take a "hands-on" portion of a certifying exam.

Who should attend?

1. Physicians and physicians-in-training looking for different osteopathic manipulative techniques to treat your patients.
2. Those Physicians seeking time-efficient techniques for the busy office.
3. Physicians who want a quick anatomy review and review of the basis of several technique modalities.
4. Physicians wanting new techniques and exercises for their patients of all ages.
5. Physicians who want to learn new methods yet have quality time with their families.

CME:

The program anticipates being approved for 22.5 hours of AOA Category 1-A CME credit pending approval by the AOA CCME.

Program Time Table:

Thursday, January 11	5:00 pm - 10:00 pm
Friday, January 12	7:00 am - 1:30 pm
Saturday, January 13	7:00 am - 1:30 pm
Sunday, January 14	7:00 am - 1:30 pm

Each day includes (2) 15 minute breaks

Course Location & Hotel Accommodations:

Disney's Contemporary Resort • Lake Buena Vista, FL
Reservation Phone #: 407/824-3869 • Group Rate: \$189.00 plus
\$25 for additional person (18 years and older) each night

Deadline for Reservations: December 11, 2006

**Registered online at: www.academyofosteopathy.org or
call Christine Harlan at 317/879-1881**

Purpose. Passion. Service.

Elements of living life with authenticity.

It's a drive from within. It's what motivates the Arctic Norwegian fishermen who have braved the sea for hundreds of years, and have passed on their skills for generations. It's a way of life.

Today, Nordic Naturals is honored to continue the tradition by providing the only 100% authentic Arctic Norwegian Cod Liver Oil. Our oils are sourced by Arctic fishermen and produced in our own plant in Arctic Norway. We adhere to the most stringent standards for purity, freshness, and potency.

Nordic Naturals authentic Arctic-D Cod Liver Oil

Pure and healthful, with a light clean taste—the way nature intended.

Gold Standard is the result of Nordic Naturals exceptional management and manufacturing standards from catch to finish. Taste the difference!

{ Arctic
Fisherman }



N O R D I C N A T U R A L S ®

For more information, please contact: 800.662.2544 x1 or visit: nordicnaturals.com

Lumbo-abdominal neuralgia

“The Practice of Osteopathy”, Carl Philip McConnell and Charles Clayton Teall.
Copyright 1906. pp 644-647

Lumbo-abdominal neuralgia involves the posterior branches of the **lumbar nerves**. Tender points are found near the vertebra, middle of the iliac crest, lower part of the rectus, and in the male occasionally in the scrotum, in the female in the labia. These are often bilateral and are usually of a constricting nature. The ilio-scrotal branch is the one most commonly affected.

Subluxations of the **vertebrae**, and other lesions, as contracted muscles, are found along the lumbar vertebrae, and even as high as the lower dorsal vertebrae. Also lesions are found at the lumbo-sacral articulation. Pelvic disease is also a cause.

A downward displacement of the **lower ribs**, eleventh and twelfth, is a common disorder and may be the cause of severe neuralgiac pains in the region of the iliac fosse. It may simulate ovarian inflammation, renal colic, or even appendicitis if on the right side. In fact, it may be a cause of inflammation of the deeper structures, such as the ovary and Fallopian tube.

A subluxation of the vertebrae at the fourth and fifth dorsals may cause severe neuralgiac pains in the epigastrium.

Neuralgia of the Spinal Column. According to medical writers, this is especially found in weakly women and after concussion of the spine, that it is a troublesome symptom in hysteria, and in many cases it is due to a reflex stimulus from diseased viscera. Most of this is undoubtedly true, but they have not found out the real significance of these neuralgiac pains. The various **tender points** along the spinal column are of paramount importance to the osteopath as a **guide** to his **diagnosis**; not only in certain cases, but in nearly every case. The tender points are not due, in nearly every instance, to reflex stimuli from diseased organs, but these tender points are the result of a local lesion and are many times the cause of the disorder to the diseased viscus. The neuralgiac pains are simply a symptom that a lesion exists in the immediate locality.

Neuralgia of the Sacral Region and Coccygodynia. This form involves the nerves in the sacral and coccygeal regions. The nerves between the bone and the skin are affected. The cause of the pain is generally due to derangement of the articulation of the **lumbar** and **sacrum**, and to severely contracted muscles over the sacral foramina; also to lower lumbar lesions. In coccygeal neuralgia, the **coccyx** is commonly displaced in any one of the various displacements that are liable to occur.

Neuralgia of the Legs and Feet. This includes the **crural form**, in which the front of the thigh is the seat of the pain; also the form in which tender points are found along the course of the **sciatic** nerve. The latter form is quite a common one, although sciatica is rarely a neuralgia. It is a neuritis and will be found classed under that heading. The tender points presented are the lumbar, sacroiliac, gluteal, peroneal, maleolar and ex-

ternal plantar. The various neuralgiac pains of the legs and feet are generally due to **lesions** of the **lumbar**, **pelvic**, and **thigh** regions. **Metatarsalgia** occurs when the fourth metatarso-phalangeal articulation is partially dislocated. Neuralgia in the heel, ball of the foot and toes may be due to local causes or to lesions higher up.

Visceral Neuralgia. This is a term applied to neuralgia of the gastro-intestinal tract, the kidneys, and the various pelvic organs.

Neuralgias are also classified, according to their character and cause, as epileptiform, reflex or sympathetic, traumatic, herpetic, hysterical, rheumatic, gouty, diabetic, anemic, malarial, syphilitic and degenerative neuralgia.

Diagnosis and Prognosis of Neuralgia. Neuralgia is to be diagnosed chiefly from neuritis, rheumatism, and the effects of severe pressure upon the nerves, in **neuritis** there is oftentimes a symmetrical affection, while in **neuralgia** there is a unilateral distribution and there are many remissions and intermissions and a varying of the pain from one place to another. In severe forms of neuritis, anesthesia succeeds the hyperesthesia of the sensory nerves. In cases of severe pressure upon nerves, the pain is continuous and neuritis will soon be manifested. In rheumatism the pain is localized in muscles or groups of muscles and does not follow the course of the nerve. The pain is increased by motion.

The prognosis is generally favorable, no matter how severe the attack. The prognosis is influenced only by the age of the patient and the cause.

Treatment of Neuralgia. Consists, first, in the control of the paroxysm and, second, in the removal of its cause. In controlling the paroxysm, frequently one will be able to remove the cause. In a large majority of neuralgias, the cause is directly due to a displaced tissue, generally a bone or muscle in the locality affected; all that is necessary in order to perform a cure is to correct the disordered tissue and the pain will cease. This usually can be done immediately, although there are cases which require several treatments before a correction of the parts can be accomplished; besides, in acute cases the involved region will be so tender that an attempt to correct the tissues sufficiently to relieve the paroxysm will be unbearable to the patient. In such instances when the cause cannot be removed at once, firm pressure or inhibition over the involved nerves for a few minutes and local application of hot water will generally disperse the pain for the time being. The rules of hygiene should be observed in all cases.

The best time to remove the cause of neuralgia is between the attacks when the tissues are not as tender or contracted to

continued on page 16

Pelvic Pain Due to Placement of the Vaginal Cuff after Hysterectomy:

Case Report and Osteopathic Manipulative Approach to Treatment

George J. Pasquarello

Abstract

Hysterectomy is performed on more than 570,000 women a year in the United States⁸ with an estimated 21.2% of U.S. women having undergone the procedure¹⁴. The most frequent indications are leiomyomas, abnormal bleeding and chronic pelvic pain³. While hysterectomy may provide for the relief of chronic pelvic pain, it may also be a cause. Common attachment sites of the vaginal cuff after hysterectomy may include the cardinal, uterosacral or sacrospinous ligaments. Proximity to levator ani and obturator internus makes injury to these muscles a risk for causing pelvic pain. A case presentation of pelvic pain secondary to obturator internus injury during attachment of the vaginal cuff will be described with a review of the anatomy of the area. After initial osteopathic evaluation and treatment, one patient had the vaginal cuff repositioned by the surgeon with significant improvement in pain. Followup osteopathic manipulative treatment alleviated most of the persistent pain symptoms.

Case Report

A patient presents with a 2-year history of pelvic pain after trans-vaginal hysterectomy.

AO is a 46 y.o.w.f. referred for evaluation of chronic low back and pelvic pain. AO states that her pain began 3 years ago after an abdominal hysterectomy was done. The indication for surgery was vaginal prolapse. After surgery, she developed a rectocele and a secondary surgery was done to repair this. It was after the second surgery that her symptoms became more significant. She complained of burning pain around the area of the pelvis with some radiation into the right gluteal and

posterior thigh region. She also complained of some rectal pain as well as right inguinal pain. She has been seen by a Physiatrist for chronic pain treatment over the past year with some minimal improvement. She has been treated with pain medications, which have given her some relief although she continues to have persistent pain. She notes that the pain is worse when moving her bowels though better afterward. She denies pain during intercourse though states that she is very sore in the inguinal and SI regions after intercourse. She is worse with sitting for long periods and feels better when walking.

A recent MRI showed some degenerative changes in the lumbar spine though no sign of disc pathology causing radiculopathy. A pelvic MRI was done which showed no anatomic explanation for her pain.

Past Medical History

Chronic low back pain and pelvic pain.

Past Surgical History

Tonsillectomy and Adenoidectomy. Bladder suspension. Hysterectomy. Rectocele repair.

Allergies

COMPAZINE, THORAZINE, CEF-TIN, DARVOCET, SOMA, INDOCIN.

Medications

Ultram 50 mg 6-8 q.d., Ativan 2 mg t.i.d., Premarin 1.25 mg q.d.

Social History

Smokes 3 packs of cigarettes per day. Denies use of alcohol, no use of illicit drugs. Was working as a Nurse's Aid, but is presently a housewife.

Family History

Father died at 65 due to Emphysema. Mother died at 53 due to Breast CA.

O: Vitals:

Temp - 97.4°F Pulse - 88
Resp - 16 BP - 116/70

General

This is a pleasant 46 y.o.w.f. who appears her stated age. She has a moderately flat affect and appears to have a significant amount of pain when moving from standing to seated to supine positions.

Neuro

Cranial nerves 2-12 are grossly intact without focal sensory or motor deficits. DTR's are +2/4 in the bilateral upper and lower extremities. Strength is +5/5 in the bilateral upper and lower extremities. Cervical compression test and straight leg raise are negative bilaterally. Dermatomes L1-S2 and C5-T2 are intact bilaterally. Babinski is downgoing bilaterally.

Structural Exam

Marked restriction is in right SI joint with severe tenderness and edema around the SI joint and along the proximal insertion of the right gluteus medius and gluteus maximus. There is a positive standing and seated flexion test on the right. There is some tenderness and swelling at the distal right multifidus insertion. Right innominate is rotated anteriorly and inferiorly, L5 ERSr, L1 FRSr. Pubic symphysis restriction is noted with inferior pubic symphysis on the right. No tenderness is noted at the sacrococcygeal ligament or along the insertion of levator ani. Focal tenderness is noted at the right lesser sciatic notch at the area of obturator

→

internus tendon. Pressure here reproduces all of AO's symptoms of pain. The pain is improved with external rotation of the femur.

Assessment

1. Pelvic pain after hysterectomy and rectocele repair.
2. Low back pain with radiation into right posterior thigh and gluteal region.
3. Somatic dysfunction of the lumbar spine, pelvis, sacrum and lower extremities.
4. Myofascial trigger point in right obturator internus secondary to surgical trauma.

Course of Treatment

Our initial treatment included counterstrain to the right obturator internus, which immediately improved AO's symptoms. When she walked around the office a bit her symptoms returned, though with much less severity.

Over the course of the next few weeks, she was treated several times primarily focusing on treating obturator internus, restoring normal lumbar and pelvic mechanics and decreasing related somatic dysfunction. The somatic dysfunction did improve significantly although the tenderness at obturator internus persisted.

Eventually a discussion with her surgeon led to laparoscopic surgery and the attachment of the vaginal cuff was moved from the original site at the sacrospinous ligament.

After surgery, AO was seen in the office and was found to have a fairly dramatic improvement in her pain symptoms. She also had improvement in her previously noted somatic dysfunction.

Over the course of the next few months, OMT was focused on the lumbar and pelvic somatic dysfunction. As her objective findings improved, AO became more functional and was able to decrease the use of pain medications.

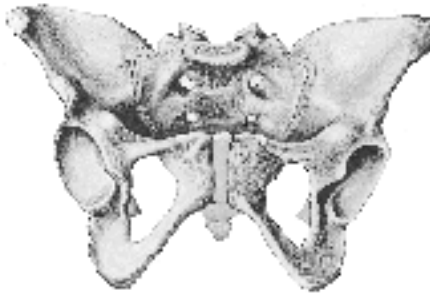Review of the Pelvic Anatomy

The following is a review of the anatomy of the pelvis and related structures. An understanding of this anatomy will be important to appreciate the potential for injury during pelvic surgery. This discussion will help clarify the possible causes of chronic pelvic pain and give some insight into useful treatment approaches.

Bony pelvis

The bony pelvis is made up of the sacrum and coccyx posteriorly and two innominate or hip bones which complete a skeletal ring and attach anteriorly in the midline at the pubic symphysis. The bony pelvis houses the pelvic organs and provides structural support as a conduit between the spine and lower extremities. Muscular attachments include muscles of the lower back, abdomen and lower extremities. There is also a muscular support for the pelvic organs at the inferior aperture or pelvic outlet.

The bony pelvis is divided into greater and lesser as well as true and false



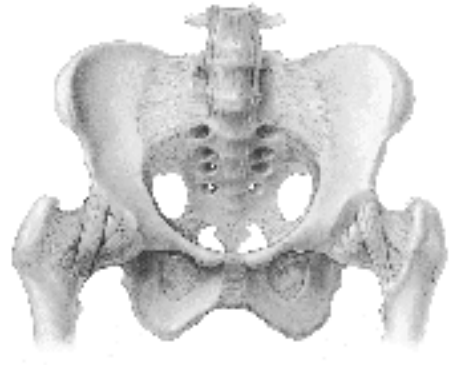segments. These divisions are helpful in discussing the relationships of structures to the bony pelvis but there is no true anatomic separation. While the primary function of the bony pelvis is locomotor, adaptations in the female pelvis allow for parturition.

The greater or false pelvis consists of the iliac flanges and sacral base cephalad to an oblique line passing through the sacral promontory and the pubic crest known as the lineae terminales. The iliac flanges provide part of the lateral and posterior walls of the pelvis and support and protect the lower abdominal organs.

The lesser or true pelvis consists of the bony structures caudad to the lineae terminales which form a more complete basin to house and protect the pelvic organs. A superior and inferior aperture bound the true pelvis from above and below respectively. The sacrum and coccyx make up the posterior border while the inferior portion of the ilium, ischium, pubic ramus and pubic symphysis make the lateral and anterior borders.¹⁸

Joints

The pubic bones meet in the anterior midline at the pubic symphysis. The bones are connected by the superior and arcuate ligaments and a fibrocartilaginous disc.



The disc is strengthened anteriorly by the inguinal ligaments and linea alba. It is better developed in females and often contains a cavity.

The sacroiliac joints are complex and provide the stability and strength in transmitting weight from the vertebral column to the lower extremities. Each joint has a network of anterior, posterior and interosseous ligaments. The iliolumbar and the anterior lumbosacral ligaments attach the lower lumbar segments to the pelvis. The sacrotuberous and sacrospinous ligaments attach the sacrum to the ischium. The sacrospinous ligament blends with the anterior margin of the sacrotuberous. The anterior surface of the sacrospinous ligament is muscular and constitutes the coccygeus muscle, which attaches to the lateral margin the coccyx.¹⁸

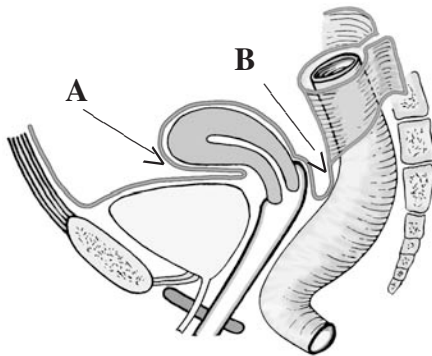
Viscera

The major structures that occupy the true pelvis in females include the rectum, uterus and bladder. The ovaries are typically positioned in the false pelvis but can be mobile. Each has an inferior attachment at the pelvic diaphragm and is retroperitoneal. The peritoneum that lies over the viscera will fold around the structures and double over onto itself forming thickenings which function as ligamentous support. The uterus is positioned between the rectum and the bladder and ascends into the abdomen during pregnancy.²¹

Uterine and cervical ligaments

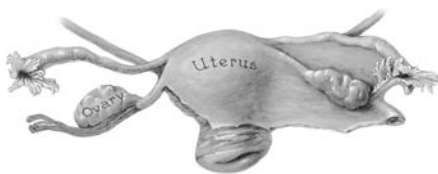The uterus is connected to the blad-

der, rectum and pelvic walls by thickenings in the peritoneum that provide mechanical support and in some cases, dynamic control. The ligaments are primarily made of peritoneal folds and are



Coronal section through the pelvis

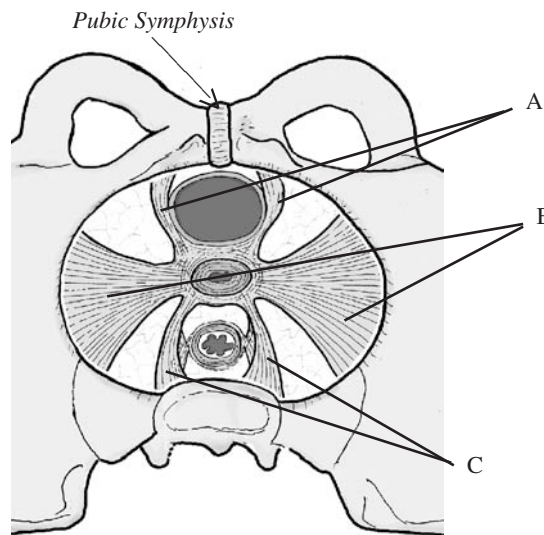
usually named by the structures that they attach. The uterovesical fold (A) is made of the anterior reflection of peritoneum between the uterus and bladder. The rectovaginal fold (B) is made of the posterior reflection of peritoneum between the rectum and posterior vaginal fornix. The uterosacral folds are made of two peritoneal reflections that pass back from the cervix uteri on each side of the rectum and attach to the anterior sacrum. These are much thicker and contain fibrous tissue and smooth muscle that provides significant support for the uterus and cervix. These are referred to as the uterosacral ligaments due to their thickness compared to the other folds.²²



The broad ligaments extend from the lateral aspect of the uterus to the lateral walls of the pelvis. They are divided into sections named by their attachments. Mesosalpinx is made of the peritoneal fold that lies over the uterine tube. Mesovarium is made of the peritoneal fold that lies over the ovary. Mesometrium is made of the peritoneal fold that lies over the uterus. The uterine round ligaments are thickenings within the mesometrium that

arise from the lateral margin of the uterus just below the lateral cornua and travel laterally to the abdominal wall, through the inguinal ring and attach to the mons pubis or as far as the labia majora.

The cervical ligaments are thick and strong condensations of connective tissue that form mechanical support for the uterus. The pubocervical ligaments (A) diverge around the urethra and attach to the posterior aspect of the pubic bones. The transverse cervical or cardinal ligaments (B) extend laterally to the pelvic wall and provide significant support. The



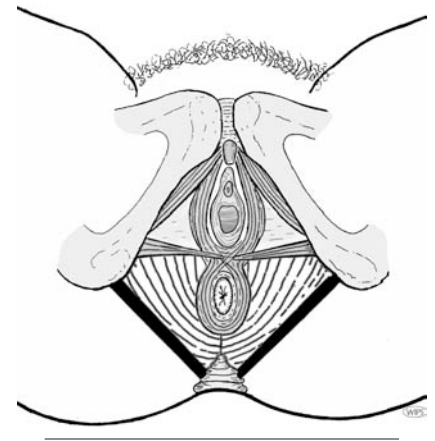
Superior view of cervical ligaments

uterosacral ligaments (C) are described above and diverge around the rectum and attach to the sacrum posteriorly. These ligaments form a ring of support for the cervix. This provides a stable base for the uterus and a strong support for the vagina.²²

Muscles

The muscles of the pelvis may be divided into categories based on function.

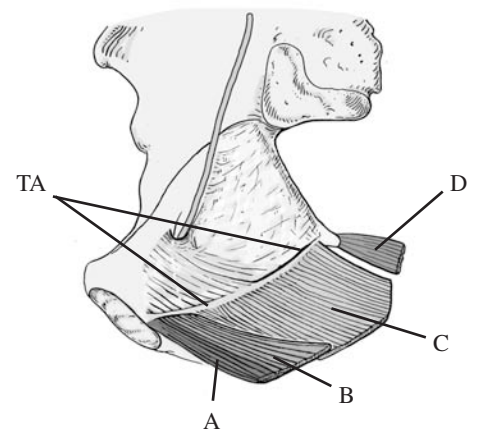
The urogenital diaphragm is superficial and attaches anteriorly to the pubic arch, posteriorly to the coccyx and laterally to the pubic and ischial rami, ischial tuberosities and sacrotuberous ligaments. This is a thin layer of muscle that provides support for the urethra, vagina and anus. The superficial transverse perinei is a thin muscular slip that attaches at the ischial tuberosity laterally and at the perineal body in the midline. The bulbospongiosus attaches laterally along the vestibular



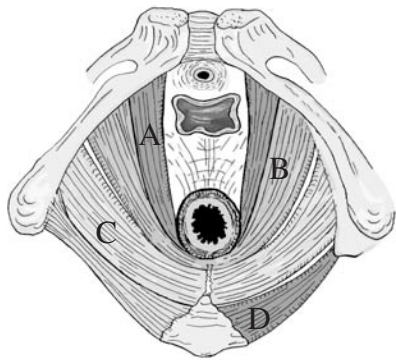
bulbs and attaches anteriorly to the corpora cavernosa of the clitoris. It attaches to the perineal body posteriorly and constricts the vaginal orifice. Ischiocavernosus attaches along the medial border of the pubic ramus and attaches anteriorly to the clitoris. Sphincter urethra surrounds the urethra and blends with the smooth muscle of the bladder neck. Compressor urethra travels deep to the ischiocavernosus and medially to the urethra. Sphincter urethrovaginalis attaches to the perineal body posteriorly and passes forward to either side of the vagina and urethra. It is thought to play an important role in continence

of urine. Sphincter ani is made of three layers of muscle: internus, externus and superficialis. These attach to the perineal body anteriorly and the coccyx posteriorly. It surrounds the anus and provides support for its function.¹⁹

→

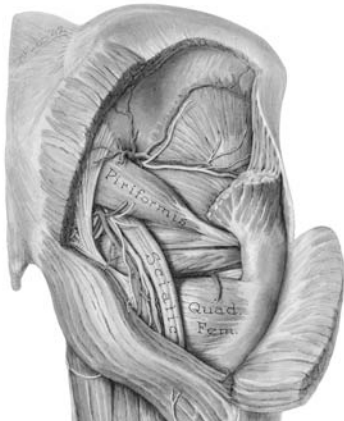


Internal view of levator ani



Inferior view of levator ani

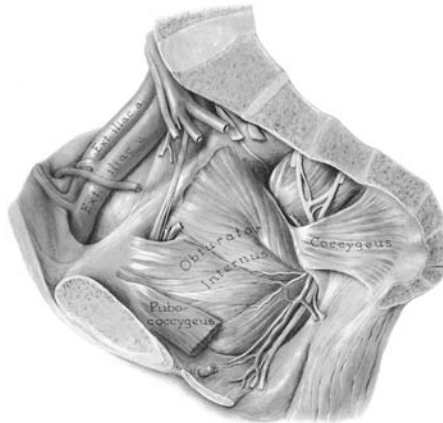The levator ani or pelvic diaphragm is made up of five muscles. These are named separately by their attachments to the bony pelvis, though they function as a group. The muscles share an attachment to a tendinous arch (TA) that support the muscles at the ischial spine posteriorly and the pubic body anteriorly. Thus pubococcygeus (A), iliococcygeus (B), ischiococcygeus (C), coccygeus (D) and the deep puborectalis form a muscular sling that provides support for the pelvic viscera and muscular resistance to increased intrapelvic pressure during respiration and aids in venous and lymphatic



return from the pelvic viscera and lower extremities.¹⁹

Muscles of the lower extremity that attach to the pelvis on its internal surface are of particular interest for this discussion. Piriformis attaches proximally to the anterior surface of the sacrum and distally to the greater trochanter. It courses through the greater sciatic foramen and its fibers often blend distally with obturator internus and the gemelli. The relationship to the sciatic nerve is often discussed as piriformis and can cause compression of

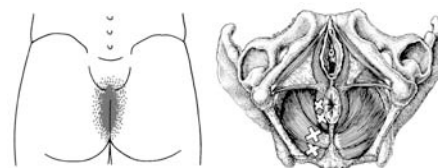the nerve with spasm. Gemellus superior and gemellus inferior attach proximally to the ischial body and tuberosity respectively. Distally, their fibers blend with obturator internus and attach to the greater trochanter. Obturator internus attaches proximally to the anterolateral wall of the lesser pelvis overlaying the obturator foramen. The fibers converge toward the lesser sciatic notch and form a tendon that turns sharply and attaches distally to the greater trochanter. The tendon passes under the ischial spine at



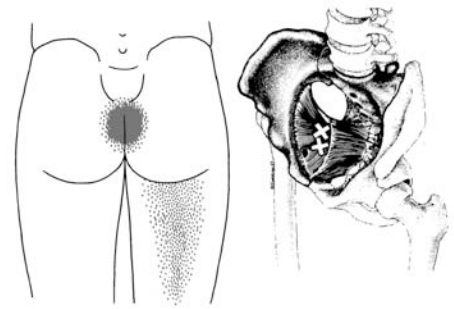
the insertion of sacrospinous ligament and coccygeus. The surface of the lesser sciatic notch is covered in hyaline cartilage and is separated from the muscle by a bursa which functions as a pulley as the muscle contracts. The body of obturator internus lies lateral to the pelvic diaphragm and its tendinous arch. These muscles function primarily as external rotators of the hip.²⁰

Myofascial trigger points of the pelvis

A myofascial trigger point is a hyperirritable spot in a skeletal muscle that is associated with a hypersensitive palpable nodule in a taut band. The spot is painful and can give rise to characteristic referred pain, referred tenderness, motor dysfunction and autonomic phenomena.¹⁶ The source of activation of pelvic trigger

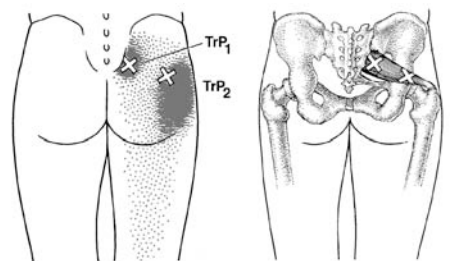


Levator ani trigger points



Obturator internus trigger points

points is thought to possibly include poor posture, sacroiliac dysfunction, chronic hemorrhoids, chronic pelvic inflammatory disorders, severe falls on the coccyx, or surgery in the pelvic region.¹⁷ Muscles of the pelvic floor may have associated trigger points causing pain to radiate to the perisacral region and the posterior thigh. Levator ani trigger points typically cause pain to radiate to the area around the coccyx. Muscles of the urogenital diaphragm typically cause pain to radiate to the genitalia. Obturator internus typically causes pain to radiate to the anococcygeal region as well as the ipsilateral posterior thigh.



Piriformis trigger points

Obturator internus trigger points may also be present as vaginal pain or a sense of rectal fullness. Piriformis typically refers pain to the buttocks, ipsilateral hip and posterior thigh.¹⁷ The pain experienced by sciatic nerve entrapment may be similar in presentation, but trigger points may occur independently.

Review of hysterectomy procedure and attachment of vaginal cuff

Hysterectomy involves the removal of the uterus and usually the cervix. The uterine tubes and ovaries may or may not be removed depending on the situation. The procedure involves isolating and

disrupting the uterine and cervical ligaments. After the uterus is removed, the cervical end of the vagina is oversewn and attached to prevent prolapse, rectocele or cystocele.

There are several options for the surgeon in selecting a site for vaginal cuff attachment. Sacrospinous ligament is a common attachment site and is known as the Richter procedure. This has been shown to be an effective treatment for patients at risk for prolapse, cystocele or rectocele formation. Long-term follow-up reports that demonstrate minimal prolapse have made this a popular option.¹¹ Uterosacral ligament is another common site of attachment. This has also been shown to be effective in providing good support and limited occurrences of prolapse, cystocele or rectocele formation.⁴ Apical vault repair involves incorporation of pubocervical fascia, uterosacral ligament and rectovaginal fascia to reestablish the pericervical ring at the vaginal apex. This recreates the anatomical relationship of the vagina to the cervical ligaments that provides good support for the cuff and helps to prevent prolapse, cystocele or rectocele formation.¹³ Formation of a fascial sling from rectus sheath has been shown to be effective, though limited study has been done on this approach.² Anterior suspension attaches the vaginal cuff to the rectus sheath anteriorly and has also been shown to be effective.⁶

Each of these options has advantages and disadvantages. Familiarity with the technical aspect of a procedure is often a reason for choosing a particular technique. Personal experience or literature review may prompt a surgeon to try a new approach.

Although the Richter procedure has a long history of experience, it has an increased risk of causing pelvic pain as a complication due to the proximity of structures to the sacrospinous ligament. Coccygeus arises from sacrospinous ligament and could easily become included in a suture attaching the cuff here. Levator ani attaches to the ischial spine at the site of the sacrospinous ligament and could also become included in a suture here. The patient described in the above case presented with an obturator internus trigger point that was relieved immediately with relaxing the muscle. Although OMT was done using several approaches, the cause of the trigger point had to be removed be-

fore symptoms could resolve. Moving the suture from its attachment at sacrospinous ligament relieved the constant irritation to obturator internus. Followup OMT improved pelvic mechanics and relieved the trigger point causing the patient's symptoms.

Pelvic pain has a 30-40% unknown etiology,^{9,12} however a search of the literature using MEDLINE^{7,9,10,15} failed to show any citations which considered an active trigger point as a result of suture placement. The literature focuses on hysterectomy as a treatment for pelvic pain but does not typically include pelvic pain as a complication. One review described nerve injury after hysterectomy,¹ but most studies focus on the incidence of prolapse as a measure of the technique's benefit. The above case illustrates how the selection of a site for vaginal cuff placement may be a risk for causing pelvic pain by injuring adjacent structures.

Osteopathic Manipulative Treatment Approach

Osteopathic manipulative treatment was utilized in the initial and follow-up care of this patient. Trigger point pressure release, stretch and spray and injection are the recommended treatments for triggerpoints. Although trigger points and Jones tenderpoints are different types of dysfunctions, counterstrain is often effective for the treatment of triggerpoints. This patient was initially treated with counterstrain to the right obturator internus as described by Jones.⁵

With the patient prone, the tenderpoint is found in the muscle belly of obturator internus on the medial aspect of the ischioanal fossa. A pain scale is established with the initial tenderness described as a 10. The thigh is internally rotated until the tenderness at the palpating finger is described as a 3 or less. Once this is achieved, the position is maintained for 90 seconds or until a pulsation is felt at the point as the tissue releases. The thigh is returned to its original position and the area may be palpated to determine if any tenderness remains. After treatment, AO reported her tenderness to be a 2 and was more comfortable sitting and walking than before treatment.

AO's symptoms improved for a short time. Improvement of this long-standing pain helped to determine that obturator internus was in fact, the cause of the pain.

Removing the suture was an important part of relieving the strain on obturator internus, however compensatory changes that had occurred over time left the patient with many dysfunctional areas. Subsequent treatment focused on restoring motion to the lumbar spine and pelvis utilizing a variety of techniques. The treatment was directed toward improving the underlying somatic dysfunction. As the somatic dysfunction improved, AO was given an exercise program focused on strengthening the muscles of the lumbar spine, pelvis and lower extremities. This approach allowed her to regain much of her decreased function.

Discussion

Understanding of anatomy and doing a thorough structural exam is important in the management of patients with chronic pelvic pain. This population has often been seen by other physicians and told there is no obvious cause for their pain. They are often depressed and frustrated from trying to find an answer. Patients are turning to many types of treatment approaches in hopes of finding a solution.

Osteopathic diagnosis and treatment provides an opportunity for patients to get a different perspective on this type of problem. By observing osteopathic principles and searching for the anatomic or physiologic cause of the problem, we are more likely to find it. Osteopathic manipulative treatment is usually effective for treating trigger points causing pelvic pain. Ischemic compression or trigger point pressure release is a manual treatment, which will decrease trigger point activity and improve local function of tissues. If the underlying cause or perpetuating factor is not addressed, the trigger point will recur. Improvement of related somatic dysfunction is imperative to optimizing function in the pelvis.

In this case, treatment addressed the mechanics of the lumbar spine and pelvis in addition to the trigger point. It is critical to address these areas in patients with pelvic pain. Pubic symphysis and sacroiliac motion are a part of the normal function of the pelvis. Restriction of motion in these joints will cause decreased function to one area and increased workload to another. It is in this way that compensatory changes can become a part of the underlying problem.

→

Identifying a problem and applying manual treatment is not always enough to resolve a patient's symptoms. A good relationship with other physicians involved with a patient's care may be an important part of management of a problem. In this case, it allowed the patient to have the cause of the problem removed and provided the gynecologist with a new perspective on the diagnosis and possible causes of pelvic pain.

References

1. Alsever JD. Lumbosacral Plexopathy After Gynecologic Surgery: Case Report and Review of the Literature. *American Journal of Obstetrics and Gynecology*. 174(6). Jun 1996.
2. Barrington JW and Calvert JP. Vaginal vault suspension for prolapse after hysterectomy using an autologous fascial sling of rectus sheath. *British Journal of Obstetrics and Gynecology*. 105(1): 83-6. Jan 1998.
3. Carlson KJ, Miller BA, and Fowler FJ, Jr. The Maine Women's Health Study: I. Outcomes of Hysterectomy. *Obstetrics and Gynecology*. 83(4): 556-65. Apr 1994.
4. Jenkins VR. Uterosacral ligament fixation for vaginal vault suspension in uterine and vaginal vault prolapse. *American Journal of Obstetrics and Gynecology*. 177(6): 1337-43. Dec 1997.
5. Jones L, Kusunose R, and Goering E. *Jones Strain-Counterstrain*. p 90. 1995.
6. Juma S. Anterior vaginal suspension for vaginal vault prolapse. *Technical Urology*. 1(3):150-6. 1995.
7. Klein T. Office Gynecology for the Primary Care Physician – Part II: Pelvic Pain, Vulvar Disease, Disorders of Menstruation, Premenstrual Syndrome and Breast Disease. *Medical Clinics of North America*. 80(2). Mar 1996.
8. Kramer MG and Reiter RC. Hysterectomy: Indications, Alternatives and Predictors. *American Family Physician*. 55(3):827-34. Feb 15, 1997.
9. Miller. Urogenital Pain Syndromes. *Anesthesia 5th Edition*. pp 1955-1956. 2000.
10. Montgomery K and Moulton A. Approach to the Patient with Menstrual or Pelvic Pain. *Primary Care Medicine 3rd Edition*. pp 615-618. 1995.
11. Richter K and Albrich W. Long-term results following fixation of the vagina on the sacrospinal ligament by the vaginal route. *American Journal of Obstetrics and Gynecology*. 141(7): 811-6. Dec 1, 1981.
12. Rosen. Emergency Medicine. *Concepts and Clinical Practice, 4th Edition*. pp 2302-03. 1998.
13. Ross JW. Apical vault repair, the cornerstone of pelvic vault reconstruction. *International Urogynecological Journal of Pelvic Floor Dysfunction*. 8(3):146-52. 1997.
14. Saraiya M, Lee NC, Blackman D, Morrow B, and McKenna MA. Self-reported Papanicolaou smears and hysterectomies among women in the United States. *Obstetrics and Gynecology*. 98(2): 269-78. Aug 2001.
15. Slocumb JC. Neurologic Factors in Chronic Pelvic Pain: Trigger Points and the Abdominal Pelvic Pain Syndrome. *American Journal of Obstetrics and Gynecology*. 149:536-543. 1984.
16. Travell J, Simons D, and Simons L. *Myofascial pain and dysfunction: The Trigger Point Manual, Vol. 1, Upper Half of the Body*. p 5. 1999.
17. Travell J and Simons D. *Myofascial Pain and Dysfunction: The Trigger Point Manual, Vol. 2, The Lower Extremities*. pp 110-131. 1992.
18. Williams P and Bannister L. *Gray's Anatomy, 38th Edition*. The Anatomical Basis of Medicine and Surgery. pp 669-678.
19. Williams P and Bannister L. *Gray's Anatomy, 38th Edition*. The Anatomical Basis of Medicine and Surgery. pp 831-835.
20. Williams P and Bannister L. *Gray's Anatomy, 38th Edition*. The Anatomical Basis of Medicine and Surgery. pp 877-879.
21. Williams P and Bannister L. *Gray's Anatomy, 38th Edition: The Anatomical Basis of Medicine and Surgery*. pp 1861-1871.
22. Williams P and Bannister L. *Gray's Anatomy, 38th Edition*. The Anatomical Basis of Medicine and Surgery. pp 1874-1875.

Note: All images are a part of the Lippincott, Williams and Wilkins Lifeart Grant's Atlas and Dissector Image Collection or the Mediclip Manual Medicine Collection. The author has a limited license for use of these images for presentation and/or publication.

Accepted for Publication: March 2002
Updating as necessary has been done by the author.

Address Correspondence to:
George J. Pasquarello, DO, FAAO
1351 S. County Trl., Bldg. 2
East Greenwich, RI 02818
E-mail: gpasquarello@kentri.org □

From the Archives
continued from page 10

such an extent as during the paroxysm. A diagnosis can then be made much more easily, and the tissues corrected with less pain to the patient.

The details (as to the locality treated) for each form of neuralgia will be found under the discussion of each variety. The general health and diet should be considered. Peterson says: "Morphine is, among the alkaloids, the most frequent cause of insanity. It is a sad commentary on the heedlessness of some medical men, but the family physician is responsible, in almost every case, for the development of the morphine habit and its far-reaching consequences. It should be looked upon as a sin to give a dose of morphine for insomnia or for any pain (such as neuralgia, dysmenorrhea, rheumatism) which is other than extremely severe and transient." □

CME QUIZ

The purpose of the quiz found on the next page is to provide a convenient means of self-assessment for your reading of the scientific content in the "Pelvic Pain Due to Placement of the Vaginal Cuff after Hysterectomy: Case Report and Osteopathic Manipulative Approach to Treatment" by George J. Pasquarello, DO, FAAO and "Non-Operative Management of Spinal Stenosis" by Philip E. Greenman DO, FAAO. For each of the questions, place a check mark in the space provided next to your answer so that you can easily verify your answers against the correct answers that will be published in the March 2007 issue of the AAOJ.

To apply for Category 2-B CME credit, transfer your answers to the AAOJ CME Quiz Application Form answer sheet on the next page. The AAO will record the fact that you submitted the form for Category 2-B CME credit and will forward your test results to the AOA Division of CME for documentation.

This CME Certification of Home Study Form is intended to document individual review of articles in the *Journal of the American Academy of Osteopathy* under the criteria described for Category 2-B CME credit.

THE AAO
JOURNAL
Official Publication of the American Academy of Osteopathy®

CME CERTIFICATION OF HOME STUDY FORM

This is to certify that I, _____,
please print full name

READ the following articles for AOA CME credits.

Questions 1-3

Name of Article: *Pelvic Pain Due to Placement of the Vaginal Cuff After Hysterectomy: Case Report and Osteopathic Manipulative Approach to Treatment*

Author: *George J. Pasquarello, DO, FAAO.*

Publication: *Journal of the American Academy of Osteopathy*, Volume 16, No. 4, December 2006, pp 11-16

Questions 4-6

Name of Article: *Non-Operative Management of Spinal Stenosis*

Author: *Philip E. Greenman, DO, FAAO*

Publication: *Journal of the American Academy of Osteopathy*, Volume 16, No. 4, December 2006, pp 18-20

Mail this page with your quiz answers to:
American Academy of Osteopathy®
3500 DePauw Blvd, Suite 1080
Indianapolis, IN 46268

Category 2-B credit may be granted for these article.

00 _____
AOA No. _____ College, Year of Graduation

Signature _____

Street Address _____

City, State, Zip _____

FOR OFFICE USE ONLY

Category: 2-B _____ Credits _____

Date: _____

AOA No. 00 _____

Physician's Name _____

Complete the quiz to the right and mail to the AAO. The AAO will forward your completed test results to the AAO. You must have a 70% accuracy in order to receive CME credits.

Answer sheet to
December 2006
AAOJ CME quiz
will appear in the
March 2007 issue.

September 2006
AAOJ CME
quiz answers:
1. D
2. C
3. C
4. A
5. B
6. B

CME QUIZ

- What percentage of women in the United States have undergone hysterectomy?
 - 5-10%
 - 10-15%
 - 20-25%
 - 30-35%
 - 40-45%
- Which of the following attachment sites for the vaginal cuff after hysterectomy is most likely to cause injury to the obturator internus muscle?
 - sacrospinous ligament
 - pubocervical fascia
 - rectovaginal fascia
 - uterosacral ligament
 - rectus sheath
- Obturator internus trigger point will cause radiating pain to which area?
 - anterior thigh
 - posterior thigh
 - low back
 - inguinal
 - lateral hip
- In spinal stenosis mobilization without impulse is used to:
 - remove disk fragments.
 - cavitate the zygapophyseal joints.
 - decongest the lateral recess canal.
 - straighten the lumbar lordosis.
- What condition in a spinal stenosis patient requires immediate surgical consultation?
 - acute cauda equina syndrome.
 - acute radicular pain.
 - acute restriction of lumbar spinal extension.
 - increasing lumbar back pain.
- To help differentiate neurogenic from vascular claudication, what type of exercise is most useful?
 - Nordic track.
 - treadmill.
 - walking on level ground.
 - exercise bicycle.

Non-Operative Management of Spinal Stenosis

Philip E. Greenman

Abstract

The diagnosis of spinal stenosis is frequently made in an aging population. Spinal stenosis surgery is the most rapidly increasing surgical procedure by spinal surgeons. The major surgical indication is lack of response to “conservative care”. A number of non-operative treatments have been advocated. This report is about 15 consecutive patients presenting with disabling back and leg pain, and significant reduction in activities of daily living. The primary treatment consisted of specific osteopathic manipulative treatment and a structured exercise program. None required surgical intervention and all noted pain reduction and increased walking tolerance.

Key Words

manipulation
non-operative care
spinal stenosis
the “Dirty Half Dozen”

Introduction

Stenosis is described as disturbed transport of substances through a canal, and as narrowing of the canal. Verbiest¹ is credited as the first to describe spinal stenosis. Lumbar spinal stenosis frequently results in a very disabling and painful condition of the lumbar spine, pelvis and extremities in an elderly population. The symptom presentation is characterized by classic neurogenic claudication² with increasing leg pain on walking. Lumbar spinal extension appears to exacerbate the symptoms. Spinal stenosis can be classified as central stenosis and lateral recess stenosis.

The central spinal canal can be round, ovoid, or trefoil. Central stenosis results from thickening of the ligamentum flavum, posterior disk bulging and degeneration, and degenerative zygapophyseal joints. The narrowed canal compromises the cauda equina. Lateral recess stenosis results from narrowing of the lateral spinal canal by hypertrophic zygapophyseal joints, posterior disk herniation and bulging, and frequently associated with spondylolisthesis. Neurogenic claudication is more commonly associated with central stenosis, and radiculopathy with lateral recess stenosis. The most common explanation of the pathology is that of neuroischemia and inflammation. Some authors³ have implicated venous engorgement while others⁴ have implicated reduction in arterial flow. Whatever the mechanism, there is some evidence⁵ that the radiographic severity predicts

disability regardless of treatment. Other researchers^{6,7} have found little correlation between anatomic severity and clinical severity.

The clinical presentation of central stenosis is from neurogenic claudication with intermittent and progressive pain on standing and walking and usually relieved by sitting and rest. It must be distinguished from vascular claudication with reduced peripheral pulses, vascular and skin changes. Neurogenic claudication frequently has deep tendon reflex changes while they are normal in vascular claudication. Placing a patient on an exercise bicycle frequently helps in distinguishing between the two. Because the neurogenic patient can lean forward while cycling, there is less narrowing of the spinal canal and thus less symptoms. The vascular claudication patient gets progressively worse while on the cycle. Patients with central stenosis have a classic body posture of forward bending at the hips and flattening or reversal of the lumbar lordosis. Lateral recess patients have radicular symptoms similar to those associated with disk protrusion with some differences in response to body position. Discogenic radiculopathies are usually relieved by recumbency and bed rest, while lateral recess stenotic radiculopathy have persistent leg pain on bed rest and seem better with sitting and allowing some spinal flexion.

Imaging studies are helpful in assessing the size of both the central and lateral spinal canals. Plain films will show significant amounts of degenerative change with productive osteophytes, disk space narrowing and degenerative changes of the zygapophyseal joints, but are not valuable for assessing canal diameters. MRI or CT studies are valuable in determining the exact dimensions of the central and lateral canals.

Recommended treatment is varied but all patients deserve a trial of non-operative care. The exact content of the non-operative care varies greatly and primarily consists of exercises to strengthen the trunk core, flexion exercises, braces, non-steroidal anti-inflammatory drugs, epidural steroids, neural mobilization, hot packs, ultrasound and manual procedures. Deyo⁸ reports that surgery for spinal stenosis is the most rapidly increasing form of spinal surgery. He also reports that in patients over 60 with demonstrable images of stenosis, twenty percent are symptom free. Surgical treatment is designed to reduce the neural compromise by decompression. In central stenosis, an unroofing procedure of the posterior elements is done to open the central canal. In lateral recess stenosis, a laminotomy and foraminotomy are indicated and successful procedures. The dilemma is to decide when a patient needs surgical decompression. All would agree that the

patient should have had the benefit of non-operative care first. The dilemma now becomes, what kind of non-operative care.

There are occasionally, patients that require surgical decompression as an urgent procedure, namely those with an acute cauda equina syndrome characterized by poor response to non-operative care, and evidence of progressive neural compromise, particularly loss of bowel and bladder control.

Material and methods: The study is a retrospective review of fifteen patients (Table 1) who were referred to a rehabilitation clinic for evaluation and treatment of disabling lumbar and lower extremity pain. Informed consent was received and approved by the IRB of Michigan State University. The pain distribution (Table 2) was primarily in the lumbar spine with major radiation to the posterior thigh and occasionally to the lower leg and feet. Four patients had previous surgery but still presented with disabling symptoms. Walking tolerance (Table 3) was assessed and graded according to the scale. A visual analog scale was used to monitor pain perception and progress during treatment.

The treatment plan was based on the premise that enhanced intra-segmental spinal motion would decrease congestion and inflammation of the compromised cauda equina and nerve roots. A combined biomechanical and respiratory-circulatory model of manual medicine was the treatment goal. The patients were assessed with a complete physical examination including a complete structural examination particularly looking for the "Dirty Half-dozen" somatic dysfunctions⁹ (Table 4). The "Dirty Half-dozen" had been found to show a high incidence in patients with disabling back and lower extremity pain syndromes. Osteopathic manual medicine procedures, primarily of the muscle energy type, were used to address the "Dirty Half-dozen" and were followed by mobilization without impulse (articulatory technique) bilaterally to each segment of the lumbar spine in the neutral range between flexion and extension. The incidence of the Dirty Half-dozen and other diagnostic finding are found in Table 5. Of particular significance, was the finding in 14 of the 15 patients (93 percent) of significant proprioceptive balance deficit demonstrated by the inability to one-legged stand with arms crossed and eyes closed. This finding is significant as a marker for imbalance of muscle control of the entire musculoskeletal system. Assessment of muscle length and strength found a cluster of findings in all these patients. They were tightness of the anterior hip capsule, the rectus femoris, psoas and iliacus, and weakness of the gluteus maximus, gluteus medius and abdominals, particularly the transversus abdominus and the abdominal obliques. An intensive physical therapy program was instituted, including manual stretching to symmetry, followed by retraining of the glutei after mobilizing the anterior hip capsules. A "sit-back" abdominal exercise program¹⁰ addressed the abdominal weakness and lack of control with gradual degrees of increasing difficulty. The exercise prescription was in four stages; first, proprioceptive balance training; second, muscle stretching to symmetry; third, retraining of weak and inhibited muscles; and fourth, aerobic conditioning of at least 20 minutes four times weekly. The exercise program was gradually moved to a home-based, patient-active self-stretching and retraining program. Contrary to the usual flexion oriented exercises, the treatment plan emphasized progressive increase in extension of the trunk and hips as muscle length and strength was restored.

Table 1 – Patient Characteristics

Male 10		Female 5
Mean Age	69.8 yrs	(Range 55-85)
Previous stenosis surgery		4

Table 2 – Pain Distribution

Lower Back	15	100%
Posterior thigh	13	87%
Calf	9	60%
Feet	3	20%

Table 3 – Walking Tolerance

Grade 1	Less than fifty feet
Grade 2	Fifty feet to two blocks
Grade 3	Two blocks to one mile
Grade 4	Over one mile

Table 4 – "Dirty Half-dozen"

1. Lumbar spine-Non-neutral vertebral dysfunction.
2. Pelvic Girdle: <ul style="list-style-type: none"> a. Pubic symphysis dysfunction. b. Innominate shear dysfunction. c. Sacral anterior nutation restriction.
3. Short leg/pelvic tilt syndrome.
4. Muscle Imbalance-Trunk and lower extremity

Table 5 – Other Diagnostic Findings

Proprioceptive balance deficit.		14	93%
Dirty Half-dozen	3	4	27%
	4	11	73%
Degenerative spondylolisthesis		7	47%
Restricted trunk extension		15	100%

Results

The treatment plan consisted of 5.6 (2-12) physician treatments and 20.0 (8-40) physical therapy visits over 8.4 (5-12) months. Walking tolerance at discharge was markedly improved (Table 6). A pain improvement scale (Table 7) assessed the patient improvement in the visual analog scale. All patients rated in the Good and Fair range at discharge. One patient was lost to follow-up and one patient died of a myocardial infarction. The remaining 13 patients were followed for a minimum of three years and five patients for more than 10 years. All were symptom-free at follow-up. During the active treatment phase one patient exhibited signs of impending acute cauda equina syndrome with bowel and bladder sphincteric weakness. He was admitted to the hospital for evaluation including neurosurgical consultation. His symptoms responded within 36 hours and surgery was not necessary. He was followed for 10 years with no return of

Initial evaluation		
Grade 1.	6	40%
Grade 2.	9	60%
Post treatment		
Grade 3.	3	20%
Grade 4.	12	80%

1. Good	>75%
2. Fair	25-75%
3. Poor	<25%
4. None	

symptoms and was physically active. One other patient who at initial evaluation had a walking tolerance of Grade 1 (less than 50 feet) responded so well that following discharge took a three-month-cruise around the world and experienced no difficulty in participating in all cruise activities and on-shore excursions.

Discussion

This retrospective study of 15 patients with spinal stenosis demonstrates the long-term value of intensive non-operative care with good long-term follow-up. The treatment plan was based on a theoretical construct that segmental mobilization of the vertebral motion segments of the lumbar spine might reduce the passive congestion in the spinal canals, both central and lateral recess, and positively influence the circulatory and inflammatory reactions at the involved neural elements. The intense and specific exercise program was viewed as a highly important and effective part of the treatment protocol. The patient's willingness to maintain the muscle balance and aerobic conditioning was an essential component of the success achieved. The patient and not the health care providers became responsible for a positive long-term outcome. It is of interest that the four patients who had previous surgery, and were still disabled, responded to the non-operative management. It may well be that their surgery was indicated and successful from the surgical perspective, but were not properly rehabilitated.

Conclusion

This study demonstrates a positive outcome in patients with spinal stenosis with a protocol geared to restoring by manual medicine treatment the functional balance of compromised anatomy and the use of mobilization without impulse techniques to mobilize and decongest the spinal segments involved. This pilot study calls for further research into the validity of the theoretical construct that mobilization without impulse does in fact reduce the passive congestion and inflammation in the spinal segments. Further research with a larger population, and with a cohort population receiving standard care but not of the type used here, would be in order. Physicians managing spinal stenosis patients might well try and add this form of manual medicine treatment, and exercise prescription, to their current non-operative care. Non-operative care in this population should be active and aggressive.

References

1. Verbiest H. A radicular syndrome from developmental narrowing of the lumbar vertebral canal. *J Bone Joint Surg (Br)* 1954;36:230.
2. Porter RW. Spinal Stenosis and Neurogenic Claudication. *Spine*. 1996;21:2046-2052.
3. Ooi Y, Mita F, and Satoh Y. Myeloscopic study on lumbar spinal canal stenosis with special reference to intermittent claudication. *Spine*. 1990;15:544-9.
4. Baker AR, Collins TA, Porter RW, Kidd C. Laser Doppler study of porcine caudate equina blood flow. The effect of electrical stimulation of the rootlets during single and double site, low-pressure compression of the caudate equina. *Spine*. 1995; 20:660-4.
5. Hurri H, Slati P, Soini J, Tallroth K, Alaranta H, Lame T, and Heliövaara M. Lumbar Spinal Stenosis: Assessment of Long-Term Outcome 12 Years After Operative and Conservative Care. *J Spinal Disorders*. 1998;11:110-115.
6. Amunsden T, Weber H, Lillias F, Nordal HJ, Abdelnoor M, and Magnaes B. Lumbar spinal stenosis: clinical and radiologic features. *Spine*. 1995;20:1178-86.
7. Jonsson B, Annertz M, Sjöbert C, Stromqvist B. A prospective and conservative study of surgically treated lumbar spinal stenosis. Part I: Clinical features related to radiographic findings. *Spine*. 1997;22:2932-7.
8. Deyo RA. Low Back Pain. *Scientific American*. August 1998;49-53.
9. Greenman PE. Syndromes of the lumbar spine, pelvis and sacrum. *Phys Med and Rehab Clinics of North America*. 1996;7:773-785.
10. Greenman PE. Exercise Principles and Prescriptions. In: Greenman PE. *Principles of Manual Medicine*, 3 ed. Baltimore MD: Lippincott, Williams & Wilkins. 2003:527.

Accepted for Publication: March 2006

Address Correspondence to:

Philip E. Greenman, DO, FAAO

3636 N. Kapok Ln.

Tucson, AZ 85719

E-mail: greenman67@cox.net ☐

MARK YOUR CALENDARS!

**AAO ANNUAL
CONVOCATION**

**MARCH 21-25, 2007
THE BROADMOOR HOTEL
COLORADO SPRINGS, CO**

PROGRAM THEME:

**NEUROMUSCULOSKELETAL
MEDICINE: AN OSTEOPATHIC
EVOLUTION**

PROGRAM CHAIRPERSON

GEORGE J. PASQUARELLO, DO, FAAO

OMT for Post-mastectomy Lymphedema and Rib Pain: Case Report

Danielle Bradshaw and Karen Snider

Abstract

A 61-year-old female status post mastectomy with lymphedema of the right arm presented with thoracic, rib, cervical, and right arm pain. The right arm was markedly enlarged with severe pitting edema extending from the fingers to the sternum and down to rib 8 on the right side. The right hemidiaphragm had restricted motion, and there was marked fascial tension across the thoracic inlet and the right axilla. Osteopathic manipulative treatment (OMT) resulted in reduction in the patient's lymphatic congestion as well her thoracic, rib, and neck pain. The primary mechanisms of treatment included releasing of strain in myofascial structures, reducing sympathetic tone, increasing efficiency of the intrinsic pumping mechanism of the abdominal diaphragm, reducing compressive forces at the right lymphatic duct, and improving postural changes caused by the edematous extremity. Lymphedema is a chronic condition which cannot be cured, but OMT may assist patients in achieving increased comfort and function.

Introduction

Lymphedema is defined as persistent edema in an extremity caused by an accumulation of protein-rich interstitial fluid in the skin and subcutaneous tissue and is commonly caused by damage to lymph nodes via surgery or radiation. Lymphedema in an extremity may cause one limb to be much larger and heavier than the contralateral limb, resulting in postural strain. Osteopathic manipulative treatment (OMT) can help to reduce fluid accumulation in the affected limb and improve associated postural strain.

Patient

Patient is a 61-year-old white female, status post right radical mastectomy for

breast cancer with right arm lymphedema and chronic mid-thoracic pain.

Chief Complaints

Patient complains of pain, numbness, and tingling in right arm; mid-thoracic pain that radiates around to the mid-axillary line; and neck pain.

History of Chief Complaints

Patient was diagnosed with cancer of the right breast 12 years ago. She had a modified radical mastectomy of the right breast at that time and subsequently developed lymphedema of the right upper extremity.

Four years ago, she had a recurrence of breast cancer, and a mass was found in her lung via CT imaging. She had a second surgery to the right breast region and is currently undergoing chemotherapy. She has had persistent pain in her mid-thoracic region, which radiates to the ribs on the right side, for the past 10 months. She rates the pain a 9 out of 10. She reports that she has been coughing frequently due to side effects of her chemotherapy. In addition, the lymphedema of her right arm has increased since she restarted chemotherapy.

Past Medical History

Right breast cancer with lung metastases, hiatal hernia, and hemorrhoids.

Past Surgical History

Right modified radical mastectomy with later radical mastectomy and rectal surgery for hemorrhoids.

Social History

Patient denies use of alcohol, tobacco, or illicit drugs.

Medications

Endodan and Soma for pain, Clari-

tin, Prilosec, and chemotherapy protocol for breast cancer.

Allergies

No known drug allergies.

Physical Exam

Vitals: BP160/70, pulse 77, respirations 17/minute, height 5'9", weight 220, BMI 31. Patient is alert; oriented to person, place, and time; and in no apparent distress. The right upper extremity is markedly enlarged with severe pitting edema extending from the fingers to the sternum and down to rib 8 on the right side. The region of edema extends posteriorly to the lateral edge of the latissimus dorsi muscle on the right. She is tender to palpation over the right serratus anterior muscle. The right hemidiaphragm has restricted motion. There is marked fascial tension across the thoracic inlet and the right axilla. The right shoulder has limited range of motion compared to the left. The right supraspinatus muscle and the right upper trapezius muscle are both in spasm.

C3-C4 are flexed, side bent right, and rotated right. The right first rib is elevated. T4 is flexed, rotated, and side bent right, which holds right rib 4 posterior. Ribs 5-7 on the right are exhaled. T5-T7 are neutral, side bent left, and rotated right.

Assessment

1) Lymphedema of the right upper extremity; 2) thoracic pain; 3) rib pain; 4) neck pain; and 5) somatic dysfunction of the thoracics, cervicals, ribs, abdomen, and upper extremity.

Plan

Based on the physical exam performed, a variety of osteopathic manipulative techniques were used to treat the somatic dysfunctions found. Direct and

indirect myofascial release techniques were used for the thoracic inlet, shoulder, axilla, and abdominal diaphragm. Articular techniques and facilitated positional release were used on the shoulder, thoracics, cervicals, and ribs. There was reduction of somatic dysfunction as well as a noticeable decrease in fluid congestion in thoracic inlet, upper chest wall, and shoulder. Additionally, she was asked to raise her right arm frequently throughout the day in order to increase fluid drainage and was advised to wear a compressive sleeve on her right arm daily. She was also instructed on gentle range of motion exercises for the shoulder. Follow-up was scheduled in three weeks. The long-term goals are to reduce fluid accumulation in the arm and improve posture and body mechanics despite the imbalance in the weight of the arms.

Patient Follow-up

With the implementation of regular evaluation and treatment every two to three months, the patient has been doing very well. The visits focus on minimizing postural strain and maximizing lymphatic drainage. The result has been a decrease in the use of pain medication. After recent CT and PET scan demonstrated no recurrence of disease, chemotherapy was stopped.

Discussion

Lymphedema is caused by an accumulation of protein-rich interstitial fluid in the skin and subcutaneous tissue which begins distally and spreads proximally. In the United States, the most common cause of lymphedema is radiation to or removal of axillary lymph nodes. It is estimated that approximately 15-35% of women who have mastectomies will develop some degree of secondary lymphedema of the upper extremity.¹ The majority of patients will not develop edema because of the ability of the body to regenerate lymphatic structures and to use collateral lymphatic channels. It is unclear why some patients are unable to utilize these compensatory mechanisms, Chronic lymphedema results in tissue fibrosis, which is caused by the chronic inflammation and hypertrophy of adipose tissue as well as frequent soft tissue infections (cellulitis).²²

There is no cure for lymphedema.

The goal of treatment must be to reduce fluid accumulation, improve limb function, normalize limb appearance, and minimize associated complications, such as cellulitis. Approaches to treatment include extremity elevation, compressive garments, pneumatic compression cuffs, exercise therapy, dietary interventions, weight loss, heat, ultrasound, gentle lymphatic massage, and special attention to skin care to reduce the risk of infection.^{1,2}

The role of surgery for treatment of lymphedema is controversial. Surgery may be indicated if there is significant functional impairment due to excessive size and weight of the extremity, severe skin changes, failure to improve with medical management, and three or more episodes of cellulitis or lymphangitis per year. Surgical procedures focus on debulking of fibrotic tissue and attempting to reestablish lymphatic drainage.^{1,2}

Manual Lymphatic Drainage

Manual lymphatic drainage therapy is a hands-on treatment equivalent to effleurage. It is commonly performed by physical and occupational therapists as well as nurses trained in manual therapy modalities.¹⁻³ Manual therapy encourages flow through collateral lymphatic pathways and typically consists of first using very gentle, rhythmic soft tissue massage techniques to regions proximal to the site of edema, followed by effleurage to the extremity.¹⁻³ The amount of pressure used in this type of treatment is described as “the weight of a feather” and is reported as optimally less than 45 mmHg.¹ The manual therapy session may be followed by the application of modalities such as heat, compression pumping, and compression wrapping.³ The manual therapist may teach the patient to perform gentle effleurage on the affected extremity at home and advise the patient on an exercise regimen that may include stretches, strength training, and aerobic training.³

Osteopathic Manipulative Treatment

Although it has not been formally studied, OMT may be of significant benefit to patients with lymphedema.⁴ The superficial lymphatics, which drain the skin, travel through the superficial fascia

and can be seen as the structural foundation supporting these lymph vessels.^{1,5} According to Zink, “gravitational forces and other stresses of life cause a drag on these fasciae, which offers considerable resistance in the large veins and lymphatic vessel.”⁶ Myofascial release and/or soft tissue techniques to the upper extremity, axilla, and shoulder region would help to open up these vessels and contribute to lymphatic drainage of the arm centrally.^{1,5-9} The lymphatics in the right upper extremity, shoulder, and axilla drain into the right lymphatic duct.^{1,10,11} Myofascial release of the thoracic inlet would encourage the right lymphatic duct to fully empty into the venous system at the junction of the jugular and subclavian veins.^{1,7,12}

Anatomic Considerations

Due to the muscular attachments, spasm in the right anterior and middle scalenes may have contributed to both the flexed dysfunctions at C3-C4 and the elevated first rib seen in this case. Releasing the scalene spasm was an important aspect of treatment and increased lymphatic flow centrally from the upper extremity. The right subclavian vein and right lymphatic duct pass directly anterior to the anterior scalene as they travel over the surface of the first rib.¹¹ Spasm in the anterior scalene and subsequent elevation of the first rib would cause compression of these structures between the first rib and the clavicle and associated soft tissues, thereby inhibiting lymphatic flow back to the venous system.^{12,13} Elevation of the first rib as well as somatic dysfunction at the cervico-thoracic junction, thoracic inlet, and anterior cervical fascia has been associated with impaired lymphatic drainage in the osteopathic literature.^{5,10,12,14-17} Treating the first rib, cervicals, and minimizing scalene muscle spasm in this patient most likely made a significant contribution to increasing lymphatic drainage of the arm.

Sympathetic Innervation and Mechanical Ventilation

Treating the thoracics and ribs in this patient contributed to increased lymphatic flow via two mechanisms. First, reduction of somatic dysfunction in the thoracics and ribs would contribute to a decrease in sympathetic tone of the region. Since

the right lymphatic duct, thoracic duct, and regional lymphatics receive adrenergic innervation from branches of intercostal nerves, reduction of somatic dysfunction and muscle tension in the upper thoracic region would contribute to dilation of associated lymph vessels via decreased sympathetic tone.^{1,5,11} Secondly, decreasing restrictions to the thoracics, ribs, diaphragm, and associated muscles would also increase the depth of breathing and, in turn, increase the pressure gradient between the chest and other structures created by respiration. This increased pressure gradient would more efficiently pull lymph centrally into the venous system.^{1,5,9,10,12} According to Zink, "If this negative intrathoracic pressure is disturbed, the return of venous blood and lymph into the thorax is inadequate. Therefore, fluids settle and are trapped in the loose fascial planes adjacent to the chest wall. The impairment of venous and lymphatic flow from the arm causes gradual build up of pressure and a progressive backing up of fluids, from the proximal to the distal portions in the fascial planes of the arm, thereby affecting the tissues of the arm."¹⁸

Postural Considerations

The increased weight of the edematous right upper extremity significantly contributed to painful somatic dysfunction in the neck, rib, and thoracic regions in this patient. The imbalance in the work required by the back and shoulder girdle muscles to hold up the heavier arm likely resulted in hypertonicity and spasm on the right, especially in the trapezius and supraspinatus. The asymmetry of the upper extremities caused the right side of the thorax to be flexed forward with rotation to the right causing significant pain and dysfunction. The patient adopted a forward-flexed posture with a non-neutral, flexed, and right-rotated segment at T4. The thoracic segments below this were neutral and rotated right with the associated ribs held in exhalation. This contributed to the minimal motion of the entire right hemidiaphragm. The postural changes described would create significant fascial strain at the transitional regions of the cervico-thoracic junction and the thoraco-lumbar junction. Due to disruption of the common compensatory patterns described by Zink and according

to Pope, "restrictions in these transitional zones can cause major alterations in the function of surrounding structures, and thus directly or indirectly influence the health of the body."¹⁹ A study by Merchant and Dekker found that 80% of women at three months post-mastectomy status had postural changes as evidenced by shoulder unleveling which was measured at the acromioclavicular joint.²⁰ Treatment of the postural changes along with optimizing lymphatic drainage should minimize the frequency and severity of the patient's pain.

Summary

In this case study, the use of OMT caused significant reduction in the patient's lymphatic congestion as well as a reduction in her thoracic, rib, and neck pain. The primary mechanisms of treatment included releasing of strain in myofascial structures, reducing sympathetic tone, increasing efficiency of the intrinsic pumping mechanism of the abdominal diaphragm, reduction of compressive forces at the right lymphatic duct, and improvement of postural changes caused by the edematous extremity. Although lymphedema is a chronic condition which cannot be cured, OMT may significantly aid patients in achieving improved posture and increased comfort and function.

References

1. Chikly BJ. *Silent Waves: Theory and Practice of Lymph Drainage Therapy*. Scottsdale, AZ. I.H.H. Publishing. 2002.
2. Abeloff MD, Armitage JO, Niederhuber JB, Kastan MB, and McKenna WG, eds. *Clinical Oncology*. 3rd ed. New York. Churchill Livingstone. 2004:817-831.
3. Frontera WR and Silver JK. *Essentials of Physical Medicine and Rehabilitation*. 1st ed. Philadelphia. Lippincott Williams & Wilkins. 2001:577-578.
4. Ota KS. Postmastectomy lymphedema: a call for osteopathic medical research [letter to the editor]. *JAOA*. 2006;106(3):1 10.
5. Degenhardt BF and Kuchera ML. Update on osteopathic medical concepts and the lymphatic system. *JAOA*. 1996;96(2):97-100.

6. Zink JG and Lawson WB. The role of pectoral traction in the treatment of lymphatic flow disturbances. *Osteopath Annals*. 1978;6(11):493-496.
7. DiGiovanna EL, Schiowitz S, and Dowling DJ. *An Osteopathic Approach to Diagnosis and Treatment*. 3rd ed. Philadelphia. Lippincott Williams & Wilkins. 2005:585-593.
8. Millard FP. *Applied Anatomy of the Lymphatics* [reprint]. *American Academy of Osteopathy Journal*. March 2004:9-15.
9. Royder JO. Fluid hydraulics in human physiology. *American Academy of Osteopathy Journal*. Summer 1997:11-16.
10. DeLaughter JP and Gamber RG. Lower extremity edema: a case report. *American Academy of Osteopathy Journal*. September 2005:27-31.
11. Woodburne RT and Burkel WE. *Essentials of Human Anatomy*. ed. Oxford. Oxford University Press. 1994:412-416.
12. Ward RC, ed. *Foundations for Osteopathic Medicine*. 1st ed. Baltimore, MD. Williams & Wilkins. 1997.
13. Simons DG, Travel JG, and Simons LS. *Myofascial Pain and Dysfunction: The Trigger Point Manual*. Vol 1. ed. Baltimore, MD. Williams & Wilkins. 1999:504-537.
14. Chikly BJ. Manual techniques addressing the lymphatic system: origins and development. *JAOA*. 2005;105(10):457-464.
15. Cooper AM. Osteopathy, breast cancer and posture. *Aust J Osteopath*. 1995;7(1):10-11.
16. Knott EM, Tune JD, Stoll ST, and Downey HF. Increased lymphatic flow in the thoracic duct during manipulative intervention. *JAOA*. 2005;105(10):447-456.
17. Speece CA and Crow WT. *Ligamentous Articular Strain: Osteopathic Manipulative Techniques for the Body*. Seattle, WA. Eastland Press. 2001:173-174.
18. Zink JG, Fetchik WD, and Lawson WB. The posterior axillary folds: a gateway for osteopathic treatment of the upper extremities. *Osteopath*

Annals. 1981;9(3):81-82.

19. Pope RE. The common compensatory pattern: its origin and relationship to the postural model. *American Academy of Osteopathy Journal.* Winter 2003:20.
20. Merchant TB and Dekker A. Osteopathic diagnostics in breast cancer therapeutics. *JAOA.* 1991;91(9):904.

Accepted for Publication: March 2006

Address Correspondence to:
Danielle Bradshaw, OMS-IV
416 Parkade Blvd.
Columbia, MO 65202
E-mail: dbradshaw@atsu.edu
or
Karen Snider, DO
ATSU, Dept. of OMM
800 W. Jefferson St.
Kirksville, MO 63501
E-mail: ksnider@atsu.edu □

Machine

"We will have to reason that man is a machine of form and power, forming its own parts and generating its own powers as it has use for them. All powers are invisible and we see effect only. We know such forces to be abundant in Nature and life is sustained by them."

Philosophy of Osteopathy, p 66.

Component Societies' CME Calendar and other Osteopathic Affiliated Organizations

January 17-20, 2007

18th Osteopathic Winter Seminar and National Clinical Update
Pinellas County Osteopathic Med. Soc.
Tradewinds Resort
St. Pete Beach, FL
CME: 27 Category 1A (anticipated)
Contact: Dr. Kenneth Webster
727/581-9069
www.pcomsociety.com

February 21-25, 2007

Midwinter Basic Course in Osteopathy in the Cranial Field
The Cranial Academy
Orlando, FL
CME: 40 Category 1A (anticipated)
Contact: The Cranial Academy
317/594-0411
www.cranialacademy.org

February 23-25, 2007

Additional Stiles/Laughlin Approaches to Still Functional Techniques
Indiana Academy of Osteopathy
Radisson Hotel at the Airport
Indianapolis, IN
CME: 20 Category 1A (anticipated)
Contact: IAO
800/942-0501 or
in Indianapolis 926-3009

February 24-28, 2007

Midwinter CME
Colorado Society of Osteo. Medicine
Keystone, CO
Contact: CSOM
303/322-1752
coloradodo.org

March 1-4, 2007

Chronic Disease Management CME
Ctavaganza
Fairmont Southampton, Bermuda
PMG, Inc.
CME: 18.5 Category 1A (anticipated)
Register online at: Bermuda@gopmg.com

March 24-25, 2007

Weekend Midyear Conference Breast Imaging Update 2007
American Osteopathic College of Radiology
Chicago, IL
Register online at: www.aocr.org

April 12-15, 2007

Functional Methods in Osteopataic Palpatory Diagnosis and Treatment, Part 1
Harry Friedman, DO, FAAO
Vail Marriott, CO
To register go to www.Biodo.com or www.sfimms.com

May 18-20, 2007

Functional Methods in Osteopataic Palpatory Diagnosis and Treatment, Part 2
Harry Friedman, DO, FAAO
Western University (COMP)
Pomona, CA
Register online at: www.Biodo.com or www.sfimms.com

June 16-20, 2007

June Basic Course
The Cranial Academy
Tucson, AZ
CME: 40 Hours Category 1A
Contact: The Cranial Academy
317/594-0411
www.cranialacademy.org

June 21-24, 2007

Annual Conference "And, I Do Mean All"
The Cranial Academy
Tucson, AZ
CME: 40 Hours Category 1A
Contact: The Cranial Academy
317/594-0411
www.cranialacademy.org

June 27-30, 2007

AACOM's Annual Meeting Collaboration: The Keystone to Success
Baltimore, MD
Register on line: www.aacom.org

September 24-28, 2007

Annual Convention Emergency and Trauma Radiology
Roca Raton, FL
American Osteopathic College of Radiology
Chicago, IL
Contact: AOCR
660/265-4011 or
800/258-AOCR

The Use of OMT in Patients with Osteoarthritis: Case Report

Tahira Zaidi and Stuart Williams

Introduction

Osteoarthritis (OA) is one of the most common joint disorders. It is an extremely common chronic disease in the elderly population and one of the major causes of disability. It is estimated that osteoarthritis is present in 30% of people aged 45 to 64 years and in 68% of people over 65 years old.¹ OA affects the hip more often in older men, while in older women the joints of the fingers are usually involved first. Some of the risk factors are obesity, overuse of a joint due to occupational factors, and repetitive microtrauma such as in athletes.

The main characteristics of this disorder are pain, limitations in the function of the joint, joint space narrowing, formations of bony outgrowths at joint margins, called osteophytes, and alterations in the bone integrity. The pain, which is often the presenting symptom, is usually a dull ache, and is accompanied by stiffness, especially with inactivity. Early in the disease the pain may be intermittent, but become more constant as the course of the disease progresses. The limit in function of the joint may be due to the pain itself, or, as Hallas et al postulated, due to pain causing “increases in muscle tension and shortening in the region, increased inflammation and edema and... [thus] restricted joint motion.”²

The pathophysiology of OA is believed to be due to an unknown number of environmental and genetic factors combining and initiating enzymes that breakdown the collagen and proteoglycans in the areas of bone at the joint surface. This breakdown produces bone cysts, releases inflammatory molecules, and thus causes pain and swelling.

There is no cure for osteoarthritis, and the natural tendency of the disease is to become worse with aging. However, there are some symptomatic therapies available which, if employed regularly and early on, may stabilize the course of OA, help decrease the pain, improve function of the joints, and lead to improved quality of life. Some of these options include exercise, physical therapy, OMT, acetaminophen, NSAIDS, glucosamine chondroitin, topical analgesics, opiate analgesics, intra-articular steroid injections, and lastly, joint replacements.

Case History

History of Present Illness

A 23-year-old Asian female presented with a chief complaint of pain in her left knee and foot. The pain became noticeable two years ago, after she was diagnosed with flat foot deformity and osteoarthritis in the left foot. The pain was most severe in the left foot, and radiated up the leg to the knee, and occasionally to the thigh too. Pain was present in the right foot too, but

of lesser severity. She reported the pain as being an average of 4 out of 10 on the left and 2 out of 10 on the right. Pain was constant and worse with prolonged standing or running. The patient takes a non-steroidal anti-inflammatory drug (NSAID) daily, and wears prescription orthotics on both feet, both with great relief of pain.

Pertinent Past Medical History

The patient reports that she has been remarkably healthy otherwise. She has never had any major illnesses, surgeries, or hospitalizations for any reason at all. Two years ago her orthopedic physician had diagnosed her with flat foot deformity due to posterior tibial tendon dysfunction, and osteoarthritis of the left ankle joint. She has no known medical allergies, but is allergic to prolonged contact (greater than two hours) with various metals. She is single, and is a full time student. She maintains a healthy diet, exercises daily, denies use of tobacco, alcohol, illicit drugs, and reports drinking two cups of caffeine per day. She takes Mobic (Meloxicam) 7.5mg per day and vitamin supplements.

Her family history revealed that her mother died of colon cancer at the age of 37, and prior to her death had Type I insulin dependant diabetes and ulcerative colitis. Her father is alive and well, as is one younger brother.

Physical Examination

Physical appearance revealed an appropriately dressed patient, in no apparent distress, alert and oriented to person, place, and date. Her blood pressure was 114/74, pulse was 60, and respirations were 16 per minute. HEENT was within normal limits. Heart was regular in rate and rhythm without murmur, click, or thrill. Lungs were clear to auscultation. Abdomen had no visible masses, no organomegaly, was non-tender, and had normal bowel sounds in all four quadrants. Neurologic exam showed DTR's to be 2/4 bilaterally in upper and lower extremities, and cranial nerves 2 through 12 were grossly intact. All pulses were 2+.

The patient's left shoulder was superior while the left iliac crest was inferior, and she had a slight left thoracolumbar scoliosis. T1 was neutral, sidebent left, rotated right, while T12-L2 were neutral, sidebent right, rotated left. The seated flexion test was positive on the right, as was the standing and compression test. Her sacrum had a right anteriorly rotated margin, and an anteriorly rotated innominate on the right. The straight leg and A/P drawer tests were negative bilaterally. Her thigh and knees had full range of motion bilaterally, however, her left foot had

→

decreased range of motion in dorsiflexion, plantar flexion, inversion, and eversion, when compared to the right foot. There was a slight varus of the left knee and the arches of her feet were flat, with the left much worse than the right.

Assessment

- 1) Flat foot deformity due to dysfunctional posterior tibial tendon (by history)
- 2) Osteoarthritis of the left foot, possibly right foot. (by history)
- 3) Somatic dysfunction of the pelvis and left lower extremity

Treatment Plan

The patient had already received x-rays and MRI's of the left foot to rule out any fractures, and had already been treated with NSAIDS and orthotics prescribed by her orthopedic physician, so she was recommended to try OMT for her pain.

Course of Treatment

The only technique utilized in the treatment of the patient's pain was ligamentous articular strain (LAS) since the physician was specialized in this form of treatment. LAS is a technique where dysfunctional tissues, in particular the ligaments around a joint, are taken in the direction of their dysfunction (ie. in the direction of ease, a method known as "indirect"), then exaggerated, and a balanced tension point is found and held till a release of the tissue or ligament occurs. The LAS treatments were carried out once a week for three weeks for a duration of 30 minutes at a time. The treatments were applied to the feet, ankles, legs, thighs, and knees bilaterally, and the sacrum, with attention being paid in particular to the ligaments of the left ankle and knee iliotibial (IT) bands on both legs, and the interosseous membrane between the tibia and fibula. All treatments were performed supine.

Results

After the first few treatments, the patient reported a significant decrease in pain, despite a reported increase in physical exercise in her occupation. Pain in her right foot went from a previous 2 out of 10 to complete relief, and pain in the left foot went from a previous 4 out of 10 to 1 out of 10. Pain in her left knee was still present however, but no longer radiated to the thigh. She now had increased range of motion in her left foot so that it was equal to the right foot. She was recommended to continue OMT treatments once every two months.

Discussion

This case was unusual in that the patient had a degenerative joint disease that is mainly present in the elder population, yet she was very young. Her young age (and active lifestyle) underscores the importance of preventive medicine and halting the progression of the disease, and prompted me to search for evidence of the benefits of OMT in osteoarthritis. When reviewing the literature, I found that there are only a limited number of trials done thus far in this area. However, the ones that are published show very promising results.

In 1997, Hallas et al used a rat model to apply osteopathic

manipulation in induced arthritic joints. By applying treatment such as passive range of motion, muscle energy, and passive myofascial stretching, the rats receiving OMT showed improved stride length, improved ankle lift, as well as improvements in measurements of knee circumference, leg extension force, and ankle extension distance.²

One of the recommendations for patients who have OA is to engage in a regular exercise routine, in particular for the affected joints. In 2004, Hoeksma et al compared exercise with manual therapy (which is provided by a physical therapist or medical doctor) when treating OA of the hip. Patients who received manual therapy showed significant improvements in hip function and reduction of pain compared to patients who did self-directed exercise.³ In addition, McReynold's and Sheridan conducted a trial utilizing OMT in an emergency setting. When comparing the efficacy of an intramuscular analgesic versus manipulation for acute neck pain, OMT was shown to be more efficacious in reducing pain intensity.⁴

The two above mentioned studies show that OMT can be effective in both the emergency department and as maintenance therapy in osteoarthritis. If OMT can be as effective or more effective than pharmacologic therapy, then the medical community should certainly consider it as among the top choices of therapy. The side effects of OMT are so rare and few, while the side effects of drugs are far more common, well established, and diverse, especially with chronic long-term use, as this patient would have to consider because of her age. Side effects of NSAIDS can include dyspepsia, gastric perforation or ulceration, impaired renal function in patients with previously decreased baseline function, platelet dysfunction, and spontaneous bleeding complications. Glucosamine side effects are uncertain, but include allergic reactions, and long-term therapy may increase insulin resistance and levels should be monitored in people with diabetes, or a strong family history, (as this patient did), while addiction is one of the major considerations for long-term opiate analgesic use.⁵ Long-term use of COX-2 selective NSAIDS such as celecoxib (Celebrex), and rofecoxib (Vioxx) have raised the controversy of whether these drugs increase the risk of heart attacks and strokes.

Conclusion

This was a case of a 23-year-old female with osteoarthritis of the left foot. Just three sessions of OMT, as an adjunctive to low-dose NSAIDS and orthotics, proved to be extremely effective in reducing pain, improving quality and range of motion, and in enabling her to maintain her physically active lifestyle. With continued OMT treatments we are hopeful that her disease progression will be slowed, if not halted, and she will be pain free. Since OA is such a common disorder, if OMT can be utilized as an effective alternate or adjunct to pharmacologic therapy, patients can be saved money and side effects, and ultimately achieve an improved quality of life.

References

1. Schnitzer TJ, Lane NE. Osteoarthritis. In Goldman L, Ausiello D (Eds.). *Cecil Textbook of Medicine*, 22nd edition. Philadelphia, PA. Saunders. 2004.
2. Hallas B, Lehman S, Bosak A, Tierney S, Galler R, Jacovina,

et al. Establishment of behavioral parameters for the evaluation of osteopathic treatment principles in a rat model of arthritis. *JAOA*. 1997 Apr. 97:4:207-14.

3. Hoeksma HL, Dekker J, Runday HK, Heering A, Van Der Lube N, Vel C et al. Comparison of manual therapy and exercise therapy in osteoarthritis of the hip: a randomized clinical trial. *Arthritis Care and Research*. 2004 Oct. 51:5:722-9.
4. McReynolds TM, Sheridan BJ. Intramuscular ketorolac versus osteopathic manipulative treatment in the management of acute neck pain in the emergency department: a randomized clinical trial. *JAOA*. 2005 Feb. 105:2:57-68.
5. Gorsline RT, Kaeding CC. The use of NSAIDS and nutritional supplements in athletes with osteoarthritis: prevalence, benefits, and consequences. *Clinics in Sports Medicine*. 2005 Jan. 24:1:71-82.

Accepted for Publication: February 2006

Address correspondence to:

Tahira Zaidi, OMS-IV
1607 Misty Bend Drive
Katy, TX 77494
or
Stuart Williams, DO
UNTHF. SC at Fort Worth/TCOM
Dept of OMM
3500 Camp Bowie Blvd
Fort Worth, TX 76107 ☐

AAO Announces Publication of 2006 Yearbook: Scott Memorial Lectures, 2nd Edition

Raymond J. Hruby, DO, FAAO, Editor

Pre-Publication Price: \$20.00

_____ **Scott Memorial Lectures, 2nd Edition @ \$20.00 + \$7 S/H in U.S. Please add \$1.00 for each additional book ordered. Write or call for foreign shipping rates.**

Total \$ amount of order: _____

Shipping Information:

Name _____

Street Address _____

(NO P.O. Box #s)

City _____ State _____ Zip _____

Daytime Phone _____

Payment Information:

VISA MC CHECK

Card No. _____

Expiration Date _____

2nd Edition Scott Lecturers include:

Paul E. Kimberly, DO, FAAO	1986
Stephen D. Blood, DO, FAAO	1987
Wayne R. English, DO, FAOCRM	1988
Philip E. Greenman, DO, FAAO	1989
Alan R. Becker, DO, FAAO	1990
J. Scott Heatherington, DO	1991
Michael J. Kuchera, DO, FAAO	1992
Martyn E. Richardson, DO, FACOP	1993
Melicien A. Tettambel, DO, FACOOG, FAAO	1995
Stanley Schiowitz, DO, FAAO	1996
William L. Johnston, DO, FAAO	1997
Raymond J. Hruby, DO, FAAO	1998
Eileen L. DiGiovanna, DO, FAAO	1999
Boyd R. Buser, DO, FACOPF	2000
John M. Jones, III, DO	2001
Robert C. Ward, DO, FAAO	2002
Richard L. VanBuskirk, DO, PhD, FAAO	2003
Dennis J. Dowling, DO, FAAO	2004
Karen M. Steele, DO, FAAO	2005
Herbert C. Miller, DO, FAAO	2006

For your copies, contact:

**American Academy of Osteopathy®
3500 DePauw Blvd., Suite 1080
Indianapolis, IN 46268
phone: (317) 879-1881; FAX: (317) 879-0563**

Diagnosis of Muscle Imbalance and Exercise Prescription

(The Greenman Protocol)



Featuring
Philip Greenman, DO, FAAO
Author of *Principles of Manual Medicine*

February 16-18, 2007
Midwestern University/AZCOM • Glendale, AZ



Program Chair
Brad S. Sandler, DO

Prerequisites:

The participant should have a basic understanding of functional anatomy and (1) Level I course or equivalent.

CME:

The program anticipates being approved for 20 hours of AOA Category 1-A CME credit pending approval by the AOA CCME.

Program Time Table:

Friday, February 16 8:00 am - 5:30 pm
Saturday, February 17 8:00 am - 5:30 pm
Sunday, February 18 8:00 am - 12:30 pm
(Friday & Saturday include (2) 15 minute breaks and a (1) hour lunch; Sunday includes a 30 minute break)

Course Location:

Midwestern University/
Arizona College of Osteopathic Medicine (AZCOM)
19777 N. 59th Avenue
Glendale, AZ 85308
www.midwestern.edu/AZCOM

Hotel Accommodations:

For hotel possibilities, visit:
www.expedia.com; www.travelocity.com;
www.priceline.com; or www.BizRate.com

Course Description: Level II

How to access muscle balance of the musculoskeletal system, particularly in reference to somatic dysfunction. The primary goal is to prescribe an exercise program and self-mobilization techniques to fit the patient's somatic dysfunction in order for the patient to manage themselves.

Learning Objectives:

1. To understand the functional anatomical connections of upper and lower quarter musculature to the proximal trunk and pelvis.
2. To introduce the concept of neuromuscular imbalance as a contribution to chronic musculoskeletal dysfunction.
3. To learn exercises to address specific somatic dysfunctions found in the vertebral column and pelvis.
4. To be able to design and sequence a home exercise program for patients to complement manual medicine.
5. To be able to instruct the patient in an exercise program based upon his/her functional goals and life-style.

REGISTRATION FORM
Greenman's Exercise Prescription
February 16-18, 2007

Full Name _____
 Nickname for Badge _____
 Street Address _____

 City _____ State _____ Zip _____
 Office phone # _____
 Fax #: _____
 E-mail: _____
 By releasing your Fax number/E-mail address, you have given the AAO permission to send marketing information regarding courses via the Fax/E-mail.
 AOA # _____ College/Yr Graduated _____

I require a vegetarian meal

(AAO makes every attempt to provide snacks/meals that will meet participant's needs. But, we cannot guarantee to satisfy all requests.)

REGISTRATION RATES

	<u>ON OR BEFORE 1/16/07</u>	<u>AFTER 1/16/07</u>
AAO Member	\$550	\$650
Intern/Resident/Student	\$450	\$550
AAO Non-Member	\$775	\$875

Membership application can be completed on line at
www.academyofosteopathy.org/membershipinfo

AAO accepts Visa or Mastercard

Credit Card # _____
 Cardholder's Name _____
 Date of Expiration _____
 Signature _____

Visceral Manipulation: Manual Thermal Diagnosis



Program Chair
Kenneth J. Lossing, DO

March 19-21, 2007

**The Broadmoor Hotel
Colorado Springs, CO**

Course Description: Level V

- Manual thermal diagnosis, covering first level, second level, linking brain with organs;
- emission-reception; and
- a review of general and local listening

In this course, the faculty introduces manual thermal diagnosis, which allows dysfunctions in the musculoskeletal system, cranial system, and the viscera, using infrared thermal projections to be found by the physician. This method is very quick and very precise, and also provides information on the chain of a lesion pattern. Thermal projections of all anatomical structures introduced in earlier courses are reviewed.

The patterns of somatization and cephalization that are occurring in the patient's organism, tracing the lesion through the central nervous system are explored. Labs work on learning recognition of "receiving" (diagnosis), and "emitting" (treating, so that the participants can become more precise in these areas, learn to not acquire the problems of the patients, and subsequently not drain their own vitality in the process.

Specific applications include finding hormonal imbalances, precise locations of problems in an abdomen, acute pelvic pain, acute thoracic pain, congestion, hepatic dysfunction, gastrointestinal and urinary dysfunction's coronary restrictions, sinusitis versus cranial restrictions, suture restrictions, specific joint restrictions, gastritis, gastroesophageal reflux, ulcers, and acute appendicitis.

Prerequisites:

The participant should have a basic understanding of functional anatomy and (1) Level II course

CME:

The program anticipates being approved for 24 hours of AOA Category 1-A CME credit pending approval by the AOA CCME.

Program Time Table:

Monday, March 19 8:00 am - 5:30 pm
 Tuesday, March 20 8:00 am - 5:30 pm
 Wednesday, March 21 8:00 am - 5:30 pm
 (Monday through Wednesday include (2) 15 minute breaks and a (1) hour lunch each day)

Hotel Accommodations:

The Broadmoor Hotel
 1 Lake Avenue, Colorado Springs, CO 80906
 www.broadmoor.com
 Reservations Phone #: 719/577-5775 or 866/837-9520
Deadline for Reservations – February 7, 2007

REGISTRATION FORM

Visceral Manipulation: Manual Thermal

March 19-21, 2007

Full Name _____

Nickname for Badge _____

Street Address _____

City _____ State _____ Zip _____

Office phone # _____

Fax #: _____

E-mail: _____

By releasing your Fax number/E-mail address, you have given the AAO permission to send marketing information regarding courses via the Fax/E-mail.

AOA # _____ College/Yr Graduated _____

I require a vegetarian meal

(AAO makes every attempt to provide snacks/meals that will meet participant's needs. But, we cannot guarantee to satisfy all requests.)

REGISTRATION RATES

ON OR BEFORE 2/19/07 AFTER 2/19/07

AAO Member	\$660	\$760
Intern/Resident/Student	\$560	\$660
AAO Non-Member	\$885	\$985

*Membership application can be completed on line at
www.academyofosteopathy.org/membershipinfo*

AAO accepts Visa or Mastercard

Credit Card # _____

Cardholder's Name _____

Date of Expiration _____

Signature _____

Book Review

Anthony G. Chila, DO, FAAO

***Progress In Fundamental Background Of Osteopathic Medicine In Russia.* Compiled by T.I. Kravchenko and G.B. Weinstein. Editor-in-chief: Yu. E. Moskalenko. St. Petersburg 2005. © Published by the Russian School of Osteopathic Medicine.**

In recent years, the American Osteopathic Association has become more involved in the expression of osteopathic interest in various countries of the world. It should be noted by the profession in the United States that *Osteopathy in the Cranial Field (OCF)* has been an area of significant interest in countries abroad. Textbooks of theory and method for this mode have been prepared and are utilized in the teaching programs and practice of individuals abroad. Now comes evidence that interest has moved into rigorous study of the tenets of OCF. The results of 10 years of study are presented as:

“The book comprises the most important publications issued in the period of 1996-2005 in Russia and abroad, and concerns the fundamental grounds of the cranial osteopathy—one of the successfully growing new branch of medicine in Russia. All the publications included are the result of close collaboration between the clinicians—Doctors of Osteopathy from Russian School of Osteopathic Medicine and the researchers from Sechenov Institute of Evolutionary Physiology and Biochemistry, Russian Academy of Science. The broad spectrum of fundamental and applied problems in cranial osteopathy is under consideration. From the positions of modern physiological science, the Primary Respiratory Mechanism and Cranial Rhythmic Impulse, the neurophysiological aspects of osteopathic treatment, the training of doctors’ palpatory perception, etc. are discussed. The original methodical complex for non-invasive evaluation of intracranial hemo- and liquid dynamics is proposed to help monitoring of osteopathic treatment. The articles are presented in language of their original publication and provided with annotations in Russian or English.”

The opportunity to peruse this volume was given through the courtesy of Viola M. Frymann, DO, FAAO, FCE. Practitioners and Researchers alike would benefit from review of the contents.

Low Back Pain: some real answers.

Brian J. Sweetman, FRCP, PhD, MD

pp. 162, incl. Index. ©2005 by Dr. Brian J. Sweetman (www.tfmublishing.com).

Available through Amazon @ www.amazon.com



This volume was forwarded for review with the hope that information might become a useful reference tool for members of the American Academy of Osteopathy. The studies forming the basis of the book extended over many years, originally based in the Department of Community Medicine at Guy’s Hospital Medical School, London. The Arthritis and Rheumatism Council funded the initial decade of research. Industrial studies were conducted in several of London’s large postal sorting offices with cooperation of volunteers, management, unions and first aiders. Thirteen chapters address the topics of: Level; Side; Diagnosis; Facet joint pattern; Rotation back strain pattern and other patterns; Severity; Timing; Treatment; Outcome criteria; Prognosis; Heavy work; Other conditions; Summary. In closing comments, the author remarks:

“If there were just three things that I would recommend a clinical practitioner to remember, they would be the following:

The osteoarthritic facet joint syndrome can often be identified in the low back (or neck) by asking the patient to bend or twist to one side and noting the side on which pain is induced. Pain on the side opposite the direction of bending is a hint.

The leg twist test can indicate a dorso-lumbar junction origin for referred pain felt in the low back. The side of a stuck leg twist will tend to match the side involved at the dorso-lumbar junction.

Rotation back strain can cause pain at rest to be felt on one side emanating from the dorso-lumbar junction and yet tests can hurt on the opposite side lower down at the lumbo-sacral junction.

For therapists and those prescribing therapy, it is suggested that some treatments are more efficacious for certain types of back pain than others, and that there are some forms of treatment that can actually make particular types of back pain worse. Thus diagnosis before treatment is very important. The various types of back pain and treatment have specific measures of outcome.”

Readers will appreciate the in-depth coverage of the scope of this common clinical problem through the extensive references cited from major interdisciplinary publications.



Wilczek, F. ARCHAEOPTERYX LOOKS UP: Speculations on the Future of Human Evolution.

Despite the apparent success of evolution as based on natural selection, an engineering perspective views this as haphazard and crude. In analysis, the design methods of evolution appear to be inefficient. The apparent success of natural selection is due to carrying out over long spans of time and via many individuals. This can be contrasted to the routine gathering of gigabytes useful information on an hourly basis through the use of eyes and brain in viewing the world. The limitations of biological evolution can be revisited, for example, through the concept of a man-machine hybrid. Even though sounding exotic, the reality is commonplace. Wearing a watch contributes to accuracy of time sense. Using a GPS system enhances the sense of place. Carrying a cell phone facilitates the ability to communicate over long distances. Some predictions for the future include: Space ventures by proxy (new species design containing a large nonbiological component); Quantum computer incorporation of human brain three-dimensionality, self-assembly and fault tolerance.

Update: NEW YORK ACADEMY OF SCIENCES MAGAZINE September-October 2006 10-13

Huang, S-W. Exploring the link between nasal allergy and sinus infection.

The proximity of the nasal passages and the sinus cavities has permitted consideration of association between allergic rhinitis and sinusitis. Epidemiologic studies of this association have been lacking. Studies which have addressed this association have shown correlation between allergic rhinitis and the pathogenesis of acute sinusitis, followed by development of chronic sinusitis. In the acute situation, the effect of nasal blowing forces contaminated nasal discharge into the sinus cavities. Mediators influence the colonization and proliferation of bacteria and the infiltration of inflammatory cells. Epithelial layer disruption is associated with purulent discharge and rapid infiltration of neutrophils. In the chronic situation, the induction of sinus inflammation is associated with introduction of allergens. Sensorineural inflammation of the epithelial lining of the sinus cavity then gives rise to the infiltration of inflammatory cells in an immunologic response. A sustained inflammatory response follows the release of cytokines, chemokines, prostaglandins and leukotrienes from the stimulation of epithelial cells and inflammatory cells.

THE JOURNAL OF RESPIRATORY DISEASES VOL. 27 NO. 10 OCTOBER 2006 435-440

Nijs, J; Meeus, M; DeMeirleir, K. Chronic musculoskeletal pain in chronic fatigue syndrome: Recent developments and therapeutic implications.

The primary feature in the diagnosis of chronic fatigue syndrome (CFS) is the exclusion of all other conditions and the presence of 6 months or more of debilitating fatigue. Worsening of symptoms typically follows previously well-tolerated levels of exercise and physical activity. The expression of chronic musculoskeletal pain more debilitating than fatigue is noted in patients with CFS. Also noted as being highly prevalent, but not seen to be clinically important, are generalized joint hypermobility and benign joint hypermobility syndrome. Pain catastrophizing accounts for a significant component of musculoskeletal pain. This is also a predictor of exercise performance in patients with CSF. Indirect evidence exists for consideration of a dysfunctional pain processing system in CFS. Response has been demonstrated to the use of incremental exercise (lengthened, accentuated oxidative stress response). This observation is applicable to explanation of muscle pain, postexertional malaise and decreased pain threshold which follow graded exercise. These observations are encouraged for application to the manual physiotherapy profession. Specific considerations include pacing self-management techniques and pain neurophysiology education.

MANUAL THERAPY VOL. 11 NO. 3 AUGUST 2006 187-191

Journal Index

BY ARTHUR:

Auburn-Dean, Ann Marie DO

Multidisciplinary approach to treatment in a 38-year-old female, restrained driver following injuries sustained in a rear-end collision Volume 16, Number 1, March 2006, pp. 33-35

Beal, Myron C. DO, FAAO

Sciatic Neuritis: A Research Study Volume 16, Number 2, June 2006, pp. 7-8

Bradshaw, Danielle OMS-IV

Case Study: OMT for Post-mastectomy Lymphedema and Rib Pain Volume 16, Number 4, December 2006, pp. 25-28

Burkette, Danielle OMS-IV

Larsen's Syndrome - A Case Report Volume 16, Number 3, September 2006, pp. 25-28

Capobianco, John D. DO, FAAO

co-Editor The Collected Writings of Robert G. Thorpe, DO, FAAO Volume 16, Number 2, June 2006, p. 29

Chila, Anthony G. DO, FAAO

Interface: Mechanisms of Spirit in Osteopathy by R. Paul Lee, DO Volume 16, Number 3, September 2006, p. 30

Clark, Robert C. DO

Post operative osteopathic manipulative protocol for delivery by students in an allopathic environment Volume 16, Number 2, June 2006, pp. 19-21

Crow, Wm. Thomas DO, FAAO

A Myofascial trigger point on the skull: Treatment improves peak flow values in acute asthma patients Volume 16, Number 1, March 2006, pp. 23-25

The Effects of Manipulation on Ligaments and Fascia from a Fluids Model Perspective Volume 16, Number 3, September 2006, pp. 13-19

Dickey, Jerry L. DO, FAAO

Crohn's Disease: A case report including the most recent theories and treatment principles Volume 16, Number 2, June 2006, pp. 22-25

Dowling, Dennis J. DO, FAAO

What if? Volume 16, Number 1, March 2006, pp. 11-21

Eland, David C. DO, FAAO

Palpatory Evidence for Viscero-somatic Influence upon the Musculoskeletal System Volume 16, Number 3, September 2006, pp. 21-24

Gamber, Russell G. DO, PMH

Larsen's Syndrome - A Case Report Volume 16, Number 3, September 2006, pp. 25-28

Greenman, Philip E. DO, FAAO

Non-Operative Management of Spinal Stenosis Volume 16, Number 4, December 2006, pp. 18-20

Hurrell, Jennifer OMS-III

Manipulation of Adhesive Capsulitis under Anesthesia Volume 16, Number 2, June 2006, pp. 27-28

Jordan, Theodore R. DO

Conceptual and Treatment Models in Osteopathy II: Sacroiliac Mechanics Revisited Volume 16, Number 2, June 2006, pp. 11-17

Dr. A. T. Still's Treating Chair Volume 16, Number 4, December 2006, pp. 7-8

Kasper, David MBA

A Myofascial trigger point on the skull: Treatment improves peak flow values in acute asthma patients Volume 16, Number 1, March 2006, pp. 23-25

Lamperti, Edward D.

THIEME Atlas of Anatomy Volume 16, Number 2, June 2006, p. 30

Lederman, E.

The Science and Practice of Manual Therapy: Physiology, Neurology and Psychology Volume 16, Number 1, March 2006, p. 37

Liem, Torsten DO

Cranial Osteopathy, Principles and Practice, second edition. Volume 16, Number 1, March 2006, p. 38

McCarty, Claudia L. DO, FAAO

Intercostal rib release Volume 16, Number 1, March 2006, pp. 26-29

McCombs, Thomas M. DO

Post operative osteopathic manipulative protocol for delivery by students in an allopathic environment Volume 16, Number 2, June 2006, pp. 19-21

McConnell, Carl Philip DO

Bronchial Asthma, Volume 16, Number 1, March 2006, pp. 8-9

The Sacrum, Volume 16, Number 2, June 2006, p. 9

Osteopathic Re-adjustment Volume 16, Number 3, September 2006, p. 11

Lumbo-abdominal Neuralgia, Volume 16, Number 4, December 2006, p. 10

Mitchell, Deana OMS-III

Crohn's Disease: A case report including the most recent theories and treatment principles Volume 16, Number 2, June 2006, pp. 22-25

Pasquarello, George J. DO, FAAO

Pelvic Pain Due to Placement of the Vaginal Cuff after Hysterectomy: Case Report and Osteopathic Manipulative Approach to Treatment Volume 16, Number 4, December 2006, pp. 11-16

River-Martinez, Sonia DO, co-Editor

The Collected Writings of Robert G. Thorpe, DO, FAAO Volume 16, Number 2, June 2006, p. 29

Rook, J. L. MPH, OMS-IV

Multidisciplinary approach to treatment in a 38-year-old female, restrained driver following injuries sustained in a rear-end collision Volume 16, Number 1, March 2006, pp. 33-35

Ross, Lawrence M. consulting editor

THIEME Atlas of Anatomy Volume 16, Number 2, June 2006, p. 30

Snider, Karen DO

Case Study: OMT for Post-mastectomy Lymphedema and Rib Pain Volume 16, Number 4, December 2006, pp. 25-28

Speece, Arthur J. DO

Manipulation of Adhesive Capsulitis under Anesthesia Volume 16, Number 2, June 2006, pp. 27-28

Steele, Karen M. DO, FAAO

One Heritage, Two Traditions; A Look to the Future Volume 16, Number 3, September 2006, pp. 7-9

Still, A. T. MD

The Army of Muscles Volume 16, Number 1, March 2006, p. 7

Teall, Charles Clayton DO

Osteopathic Re-adjustment Volume 16, Number 3, September 2006, p. 11

Bronchial Asthma, Volume 16, Number 1, March 2006, pp. 8-9

The Sacrum, Volume 16, Number 2, June 2006, p. 9

Lumbo-abdominal Neuralgia Volume 16, Number 4, December 2006, p. 10

Williams, Stuart F. DO

Manipulation of Adhesive Capsulitis under Anesthesia Volume 16, Number 2, June 2006, pp. 27-28

BY SUBJECT**Adhesive capsulitis**

Manipulation of Adhesive Capsulitis under Anesthesia; Hurrell, Jennifer OMS-III; Arthur J. Speece, DO and Stuart F. Williams, DO Volume 16, Number 2, June 2006, pp. 27-28

Asthma

A Myofascial trigger point on the skull: Treatment improves peak flow values in acute asthma patients; Crow, Wm. Thomas DO, FAAO; David Kasper, MBA Volume 16, Number 1, March 2006, pp. 23-25

Intercostal

Rib release; McCarty, Claudia L. DO, FAAO; Volume 16, Number 1, March 2006, pp. 26-29

Book Review

The Science and Practice of Manual Therapy: Physiology, Neurology and Psychology; Lederman, E. ; Volume 16, Number 1, March 2006, p. 37;

Cranial Osteopathy, Principles and Practice, second edition.; Liem, Torsten DO; Volume 16, Number 1, March 2006, p. 38;

The Collected Writings of Robert G. Thorpe, DO, FAAO; Capobianco, John D. DO, FAAO, co-Editor; Sonia Rivera-Martinez, DO, co-Editor Volume 16, Number 2, June 2006, p. 29;

THIEME Atlas of Anatomy; Ross, Lawrence M. consulting editor; Edward D. Lamperti, consulting editor Volume 16, Number 2, June 2006, p. 30;

Interface: Mechanisms of Spirit in Osteopathy by R. Paul Lee, DO; Chila, Anthony G. DO, FAAO; Volume 16, Number 3, September 2006, p. 30;

Case Report

Pelvic Pain Due to Placement of the Vaginal Cuff after Hysterectomy: Case Report and Osteopathic Manipulative Approach to Treatment; Pasquarello, George J. DO, FAAO; Volume 16, Number 4, December 2006, pp. 11-16;

OMT for Post-mastectomy Lymphedema and Rib Pain; Bradshaw, Danielle OMS-IV; Karen Snider, DO Volume 16, Number 4, December 2006, pp. 25-89;

Crohn's Disease

Crohn's Disease: A case report including the most recent theories and treatment principles; Mitchell, Deana OMS-III; Jerry L. Dickey, DO, FAAO Volume 16, Number 2, June 2006, pp. 22-25

Dig On

The Army of Muscles; Still, A.T. MD; Volume 16, Number 1, March 2006, p. 7;

Sciatic Neuritis: A Research Study; Beal, Myron C. DO, FAAO; Volume 16, Number 2, June 2006, pp. 7-8

One Heritage, Two Traditions; A Look to the Future; Steele, Karen M. DO, FAAO, Volume 16, Number 3, September 2006, pp. 7-9

Dr. A. T. Still's Treating Chair; Jordan, Theodore DO; Volume 16, Number 4, December 2006, pp. 7-8

Fascia

The Effects of Manipulation on Ligaments and Fascia from a Fluids Model Perspective; Crow, Wm. Thomas DO, FAAO; Volume 16, Number 3, September 2006, pp. 13-19;

Fluids Model Perspective

The Effects of Manipulation on Ligaments and Fascia from a Fluids Model Perspective; Crow, Wm. Thomas DO, FAAO; Volume 16, Number 3, September 2006, pp. 13-19

From the Archives

Bronchial Asthma (from The practice of Osteopathy, pp. 517-521); McConnell, Carl Philip DO; Charles Clayton Teall, DO Volume 16, Number 1, March 2006, pp. 8-9

The Sacrum

McConnell, Carl Philip DO; Charles Clayton Teall, DO Volume 16, Number 2, June 2006, p. 9

Osteopathic Re-adjustments

McConnell, Carl Philip DO; Charles Clayton Teall, DO Volume 16, Number 3, September 2006, p. 11

Lumbo-abdominal Neuralgia

McConnell, Carl Philip DO; Charles Clayton Teall, DO Volume 16, Number 4, December 2006, p. 10

HVLA

Crohn's Disease: A case report including the most recent theories and treatment principles; Mitchell, Deana OMS-III; Jerry L. Dickey, DO, FAAO Volume 16, Number 2, June 2006, pp. 22-25

Larsen's Syndrome

Larsen's Syndrome - A Case Report; Burkette, Danielle OMS-IV; Russell G. Gamber, DO, MPH Volume 16, Number 3, September 2006, pp. 25-28

Ligaments

The Effects of Manipulation on Ligaments and Fascia from a Fluids Model Perspective; Crow, Wm. Thomas DO, FAAO; Volume 16, Number 3, September 2006, pp. 13-19;

Lymphatic Pump Technique

Post operative osteopathic manipulative protocol for delivery by students in an allopathic environment; Clark, Robert C. DO; Thomas M. McCombs, DO Volume 16, Number 2, June 2006, pp. 19-21

Crohn's Disease: A case report including the most recent theories and treatment principles; Mitchell, Deana OMS-III; Jerry L. Dickey, DO, FAAO Volume 16, Number 2, June 2006, pp. 22-25

Muscle Energy

Crohn's Disease: A case report including the most recent theories and treatment principles; Mitchell, Deana OMS-III; Jerry L. Dickey, DO, FAAO Volume 16, Number 2, June 2006, pp. 22-25

Myofascial Trigger Point

A Myofascial trigger point on the skull: Treatment improves peak flow values in acute asthma patients; Crow, Wm. Thomas DO, FAAO; David Kasper, MBA Volume 16, Number 1, March 2006, pp. 23-25

Non-operative Care

Non-Operative Management of Spinal Stenosis; Greenman, Philip E. DO, FAAO; Volume 16, Number 4, December 2006, pp. 18-20

OMT

A Myofascial trigger point on the skull: Treatment improves peak flow values in acute asthma patients; Crow, Wm. Thomas DO, FAAO; David Kasper, MBA Volume 16, Number 1, March 2006, pp. 23-25

Intercostal rib release; McCarty, Claudia L. DO, FAAO; Volume 16, Number 1, March 2006, pp. 26-29

Multidisciplinary approach to treatment in a 38-year-old female, restrained driver following injuries sustained in a rear-end collision; Rook, J. L. MPH, OMS-IV; Ann Marie Auburn-Dean, DO Volume 16, Number 1, March 2006, pp. 33-35

Conceptual and Treatment Models in Osteopathy II: Sacroiliac Mechanics Revisited; Jordan, Theodore R. DO; Volume 16, Number 2, June 2006, pp. 11-17

Post operative osteopathic manipulative protocol for delivery by students in an allopathic environment; Clark, Robert C. DO; Thomas M. McCombs, DO Volume 16, Number 2, June 2006, pp. 19-21

Crohn's Disease: A case report including the most recent theories and treatment principles; Mitchell, Deana OMS-III; Jerry L. Dickey, DO, FAAO Volume 16, Number 2, June 2006, pp. 22-25

Manipulation of Adhesive Capsulitis under Anesthesia; Hurrell, Jennifer OMS-III; Arthur J. Speece, DO and Stuart F. Williams, DO Volume 16, Number 2, June 2006, pp. 27-28

Larsen's Syndrome - A Case Report; Burkette, Danielle OMS-IV; Russell G. Gamber, DO, MPH Volume 16, Number 3, September 2006, pp. 25-28;

The Effects of Manipulation on Ligaments and Fascia from a Fluids Model Perspective; Crow, Wm. Thomas DO, FAAO; Volume 16, Number 3, September 2006, pp. 13-19

Palpatory Evidence for Viscero-somatic Influence upon the Musculoskeletal System; Eland, David C. DO, FAAO; Volume 16, Number 3, September 2006, pp. 21-24

Pelvic Pain Due to Placement of the Vaginal Cuff after Hysterectomy: Case Report and Osteopathic Manipulative Approach to Treatment; Pasquarello, George J. DO, FAAO; Volume 16, Number 4, December 2006, pp. 11-16

Non-Operative Management of Spinal Stenosis; Greenman, Philip E. DO, FAAO; Volume 16, Number 4, December 2006, pp. 18-20

Case Study: OMT for Post-mastectomy Lymphedema and Rib Pain; Bradshaw, Danielle OMS-IV; Karen Snider, DO Volume 16, Number 4, December 2006, pp. 25-28

Pelvic Pain

Pelvic Pain Due to Placement of the Vaginal Cuff after Hysterectomy: Case Report and Osteopathic Manipulative Approach to Treatment; Pasquarello, George J. DO, FAAO; Volume 16, Number 4, December 2006, pp. 11-16

Post-Operative Pain

Post operative osteopathic manipulative protocol for delivery by students in an allopathic environment; Clark, Robert C. DO; Thomas M. McCombs, DO Volume 16, Number 2, June 2006, pp. 19-21

Post-mastectomy Lymphedema

Case Study: OMT for Post-mastectomy Lymphedema and Rib Pain; Bradshaw, Danielle OMS-IV; Karen Snider, DO Volume 16, Number 4, December 2006, pp. 25-28

Rib Pain

Case Study: OMT for Post-mastectomy Lymphedema and Rib Pain; Bradshaw, Danielle OMS-IV; Karen Snider, DO Volume 16, Number 4, December 2006, pp. 25-28

Rib Raising Technique

Post-operative osteopathic manipulative protocol for delivery by students in an allopathic environment; Clark, Robert C. DO; Thomas M. McCombs, DO Volume 16, Number 2, June 2006, pp. 19-21

Sacroiliac Mechanics

Conceptual and Treatment Models in Osteopathy II: Sacroiliac Mechanics Revisited; Jordan, Theodore R. DO; Volume 16, Number 2, June 2006, pp. 11-17

Sacrum

Conceptual and Treatment Models in Osteopathy II: Sacroiliac Mechanics Revisited; Jordan, Theodore R. DO; Volume 16, Number 2, June 2006, pp. 11-17

Scoliosis

Larsen's Syndrome - A Case Report; Burkette, Danielle OMS-IV; Russell G. Gamber, DO, MPH Volume 16, Number 3, September 2006, pp. 25-28

Soft Tissue Technique

Post-operative osteopathic manipulative protocol for delivery by students in an allopathic environment; Clark, Robert C. DO; Thomas M. McCombs, DO Volume 16, Number 2, June 2006, pp. 19-21

Somatic Dysfunction

Palpatory Evidence for Viscero-somatic Influence upon the Musculoskeletal System; Eland, David C. DO, FAAO; Volume 16, Number 3, September 2006, pp. 21-24

Spinal Stenosis

Non-Operative Management of Spinal Stenosis; Greenman, Philip E. DO, FAAO; Volume 16, Number 4, December 2006, pp. 18-20

Thomas L. Northup Lecture

What if?; Dowling, Dennis J. DO, FAAO; Volume 16, Number 1, March 2006, pp. 11-21

Thoracic Somatic Dysfunction

Crohn's Disease: A case report including the most recent theories and treatment principles; Mitchell, Deana OMS-III; Jerry L. Dickey, DO, FAAO Volume 16, Number 2, June 2006, pp. 22-25

Trigger Point Injections

Multidisciplinary approach to treatment in a 38-year-old female, restrained driver following injuries sustained in a rear-end collision; Rook, J. L. MPH, OMS-IV; Ann Marie Auburn-Dean, DO Volume 16, Number 1, March 2006, pp. 33-35

Viscero-Somatic

Palpatory Evidence for Viscero-somatic Influence upon the Musculoskeletal System; Eland, David C. DO, FAAO; Volume 16, Number 3, September 2006, pp. 21-24

Whiplash

Multidisciplinary approach to treatment in a 38-year-old female, restrained driver following injuries sustained in a rear-end collision; Rook, J. L. MPH, OMS-IV; Ann Marie Auburn-Dean, DO Volume 16, Number 1, March 2006, pp. 33-35

Contemporary OMT January 11-14, 2007

The Contemporary Hotel at Walt Disney World®, Lake Buena Vista, FL

Course Description: Level II

This innovative new Academy course will have you addressing your patient’s needs by looking at the tissue type of dysfunction and using techniques to address those dysfunctions. New techniques will be presented along with a review of pertinent anatomy/physiology (why it works). Diagnosis of joint, “muscle” and fascial dysfunctions will be addressed. HVLA, ME, CS, FPR, Still, MFR, Cranial and energy/fluid techniques will be presented. There will be an opportunity for the participants to “bring your most difficult case” to the faculty for troubleshooting. This program merges parts of the popular OMT Update with new treatment ideas. This is a course for those physicians looking for something new, those wishing to “tune up their fingers” and those planning to take a “hands-on” portion of a certifying exam.

Who should attend?

1. Physicians and physicians-in-training looking for different osteopathic manipulative techniques to treat your patients.
2. Those Physicians seeking time efficient techniques for the busy office.
3. Physicians who want a quick anatomy review and review of the basis of several technique modalities.
4. Physicians wanting new techniques and exercises for their patients of all ages.
5. Physicians who want to learn new methods yet have quality time with their families.

Program Time Table:

Thursday, January 11 5:00 pm - 10:00 pm
 Friday, January 12 7:00 am - 1:30 pm
 Saturday, January 13 7:00 am - 1:30 pm
 Sunday, January 14 7:00 am - 1:30 pm
 Each day includes (2) 15 minute breaks

Course Location & Hotel Accommodations:

Disney’s Contemporary Resort
 Lake Buena Vista, FL
 Reservation Phone #: 407/824-3869
 Group Rate: \$189.00 plus
 \$25 for additional person (18 years and older) each night

Deadline for Reservations: December 11, 2006

CME:

The program anticipates being approved for 22.5 hours of AOA Category 1-A CME credit pending approval by the AOA CCME.

REGISTRATION FORM
Contemporary OMT
January 11-14, 2007

Full Name _____

Nickname for Badge _____

Street Address _____

City _____ State _____ Zip _____

Office phone # _____

Fax #: _____

E-mail: _____

By releasing your Fax number/E-mail address, you have given the AAO permission to send marketing information regarding courses via the Fax/E-mail.

AOA # _____ College/Yr Graduated _____

I require a vegetarian meal

(AAO makes every attempt to provide snacks/meals that will meet participant’s needs. But, we cannot guarantee to satisfy all requests.)

REGISTRATION RATES

ON OR BEFORE 12/11/06 AFTER 12/11/06

AAO Member	\$630	\$730
Intern/Resident/Student	\$530	\$630
AAO Non-Member	\$885	\$995

*Membership application can be completed on line at
www.academyofosteopathy.org/membershipinfo*

AAO accepts Visa or Mastercard

Credit Card # _____

Cardholder’s Name _____

Date of Expiration _____

Signature _____



3500 DePauw Boulevard, Suite 1080
Indianapolis, IN 46268

ADDRESS SERVICE REQUESTED

NON-PROFIT ORG.
U.S. POSTAGE
PAID
PERMIT #14
CARMEL, INDIANA



Mark Your Calendars!
AAO Annual Convocation
March 21-25, 2007
The BRO^ADMOOR Hotel • Colorado Springs

Program Theme

**Neuromusculoskeletal Medicine:
An Osteopathic Evolution**

Program Chairperson

George J. Pasquarello, DO, FAAO